

# The Haemophilic Joints New Perspectives

Edited by

E.C. Rodriguez-Merchan

MD, PhD

*Consultant Orthopaedic Surgeon*

*Service of Traumatology and Orthopaedic Surgery*

*Haemophilia Centre*

*La Paz University Hospital*

*Madrid, Spain*



**Blackwell**  
Publishing



# The Haemophilic Joints New Perspectives

Edited by

E.C. Rodriguez-Merchan

MD, PhD

*Consultant Orthopaedic Surgeon*

*Service of Traumatology and Orthopaedic Surgery*

*Haemophilia Centre*

*La Paz University Hospital*

*Madrid, Spain*



**Blackwell**  
Publishing

# Dedicated to my wife Hortensia

© 2003 by Blackwell Publishing Ltd  
Blackwell Publishing, Inc., 350 Main Street, Malden, Massachusetts 02148-5018, USA  
Blackwell Publishing Ltd, 9600 Garsington Road, Oxford OX4 2DQ, UK  
Blackwell Publishing Asia Pty Ltd, 550 Swanston Street, Carlton South, Victoria 3053, Australia  
Blackwell Verlag GmbH, Kurfürstendamm 57, 10707 Berlin, Germany

The right of the Authors to be identified as the Authors of this Work has been asserted in accordance with the Copyright, Designs and Patents Act 1988.

All rights reserved. No part of this publication may be reproduced, stored in a retrieval system, or transmitted, in any form or by any means, electronic, mechanical, photocopying, recording or otherwise, except as permitted by the UK Copyright, Designs and Patents Act 1988, without the prior permission of the publisher.

First published 2003 by Blackwell Publishing Ltd

Library of Congress Cataloging-in-Publication Data

The haemophilic joints: new perspectives/editor, E.C. Rodriguez-Merchan.

p. ; cm.

Includes bibliographical references and index.

ISBN 1-4051-1230-1

1. Joints—Surgery. 2. Hemophilia—Complications.

3. Joints—Diseases.

[DNLM: 1. Hemophilia A—complications. 2. Synovitis.

3. Hemarthrosis. 4. Orthopedic Procedures. WE 300 H134 2003]

I. Rodriguez-Merchan, E.C.

RD686 .H246 2003

616.7'2—dc21

2002153101

ISBN 1-4051-1230-1

A catalogue record for this title is available from the British Library

Set in 9/12pt Sabon by Graphicraft Limited, Hong Kong  
Printed and bound in the United Kingdom at the Bath Press, Bath

Commissioning Editor: Gina Almond  
Production Editor: Fiona Pattison  
Production Controller: Kate Charman

For further information on Blackwell Publishing, visit our website:  
<http://www.blackwellpublishing.com>

# Contents

Contributors, v

Preface, viii

## **Part 1: General principles**

- 1 Orthopaedic surgery for persons with haemophilia: general principles, 3  
*E.C. Rodriguez-Merchan*
- 2 Pathogenesis of haemophilic synovitis and arthropathy, 12  
*G. Roosendaal and F.P.J.G. Lafeber*
- 3 Haemophilic haemarthrosis, 17  
*M. Betsy and M.S. Gilbert*
- 4 Haematological substitutive treatment of haemophilic haemarthroses, 20  
*M. Quintana, J. Gracia, V. Jimenez-Yuste, J. Gago, A. Villar and F. Hernandez-Navarro*
- 5 Diagnosis by imaging of haemophilic joints, 24  
*R. Nuss and R.F. Kilcoyne*
- 6 Sonography of haemophilic joints, 30  
*D. Bernabeu-Taboada and C. Martin-Hervas*
- 7 Musculoskeletal outcomes research in haemophilia, 36  
*E.C. Rodriguez-Merchan and H. de la Carte*
- 8 Joint evaluation instruments in haemophilia, 45  
*M.J. Manco-Johnson and S.M. Funk*
- 9 Joint surgery in patients with inhibitors, 56  
*S. Schulman for the rFVIIa-CI Group*

## **Part 2: Chronic haemophilic synovitis**

- 10 Multilevel surgery in a single operative session for persons with haemophilia: considerations in patients with multiple deformities, 65  
*A. Llinas and L. Heijnen*
- 11 Radioactive isotopes for radiosynoviorthesis, 68  
*J. Coya-Viña, M. Marin-Ferrer and L.M. Martin-Curto*
- 12 Synoviorthesis in haemophilia, 73  
*E.C. Rodriguez-Merchan, J.V. Luck Jr, M. Silva and M. Quintana*
- 13 Oxytetracycline clorhydrate as a new material for chemical synoviorthesis in haemophilia, 80  
*F. Fernandez-Palazzi, R. Viso, R. Bernal, G. Capetillo and H. Caviglia*
- 14 Arthroscopic synovectomy of the knee, 84  
*J.D. Wiedel*

## **Part 3: Moderate haemophilic arthropathy**

- 15 New concepts regarding articular cartilage preservation in persons with haemophilia, 89  
*M. Heim and T. Wallny*

- 16 Knee malalignments in haemophilia: osteotomies, 91  
*T. Wallny, A. Saker, H.H. Brackmann, C. Nicolay and C.N. Kraft*
- 17 Knee joint débridement in haemophilia, 96  
*H.H. Eickhoff*
- 18 Flexion contractures of the knee in haemophilia, 99  
*M. Silva and J.V. Luck Jr*
- 19 Flexion contracture of the ankle in haemophilia, 106  
*A. Llinas*
- Part 4: Severe haemophilic arthropathy**
- 20 Total hip replacement in the haemophilic patient, 111  
*E.C. Rodriguez-Merchan, J.A. Riera and J.D. Wiedel*
- 21 Total knee replacement in the haemophilic patient, 116  
*E.C. Rodriguez-Merchan, J.V. Luck Jr, M. Silva, J.A. Riera, J.D. Wiedel, N.J. Goddard, M. Heim and P.L. Solimeno*
- 22 Elbow arthropathy in patients with severe haemophilia, 125  
*N.J. Goddard*
- 23 Ankle arthrodesis in haemophilia, 129  
*J. Galina and M.S. Gilbert*
- Part 5: Rehabilitation and physiotherapy**
- 24 Prevention and treatment of joint problems in children with haemophilia, 133  
*L. Heijnen and P.J.M. Helders*
- 25 Rehabilitation and physiotherapy for adults with haemophilia, 138  
*F. Querol and K. Beeton*
- 26 Rehabilitation following ankle surgery in haemophilia, 146  
*B.M. Buzzard and P.J. Briggs*
- Part 6: Miscellaneous**
- 27 Motion analysis in children with haemophilia, 155  
*A. Seuser, T. Wallny, G. Schumpe, H.H. Brackmann and C. Kramer*
- 28 The haemophilic shoulder, 163  
*C.J. Petersson*
- 29 Osteonecrosis of the femoral head in haemophilia, 167  
*I. Hvid*
- 30 Haemophilic arthropathy of the ankle, 171  
*N.J. Goddard*
- 31 Neurological lesions following musculoskeletal bleeding in haemophilia, 176  
*J. York*
- 32 Osteophytes, subchondral cysts and intraosseous cysts of the haemophilic joints, 181  
*H. Caviglia, G. Galatro, N. Vatani, F. Fernandez-Palazzi and R. Perez-Bianco*
- 33 Haemophilic arthropathies: comparison between clinical, radiographical and subjective findings, 187  
*T. Wallny, L. Labaye, H.H. Brackmann, A. Seuser and C.N. Kraft*
- Index, 195

# Contributors

## **K. Beeton PT**

*Principal Lecturer, Department of Physiotherapy, University of Hertfordshire, College Lane, Hatfield, Hertfordshire, UK; and Honorary Lecturer, Royal Free and University College Medical School, University College, London, UK*

## **D. Bernabeu-Taboada MD**

*Consultant Radiologist, Department of Radiology, La Paz University Hospital, Madrid, Spain*

## **R. Bernal MD**

*Head Orthopedic Surgeon, Mexican Haemophilia Association, Mexico City, Mexico*

## **M. Betsy MD**

*Department of Orthopedics, Mount Sinai Medical Center, New York, NY, USA*

## **H.H. Brackmann MD**

*Director, Haemophilia Care Unit (Institute for Experimental Haematology and Transfusion Medicine), University of Bonn, D-53105 Bonn, Germany*

## **P.J. Briggs PM, Bsc, MD, FRCS**

*Consultant Orthopaedic Surgeon, Department of Orthopaedic Surgery, Freeman Hospital, Heaton, Newcastle upon Tyne, UK*

## **B.M. Buzzard PT**

*Superintendent Physiotherapist, Regional Comprehensive Care Haemophilia Centre, Royal Victoria Infirmary, Queen Victoria Road, Newcastle upon Tyne, UK*

## **G. Capetillo MD**

*Head Orthopedic Surgeon, Tabasco State Haemophilia Association, Mexico*

## **H. de la Corte MD, PhD**

*Consultant Rehabilitation, Service of Rehabilitation, Doce de Octubre University Hospital, Madrid, Spain*

## **H. Caviglia MD**

*Consultant Orthopaedic Surgeon, Argentinian Haemophilia Foundation, Soler 3485, C.P. 1425, Buenos Aires, Argentina*

## **J. Coya-Viña MD**

*Department of Nuclear Medicine, La Paz University Hospital, Madrid, Spain*

## **H.H. Eickhoff MD**

*Consultant Orthopaedic Surgeon, Orthopaedic Hospital St. Josef, Troisdorf, Germany*

## **F. Fernandez-Palazzi MD**

*Head, Orthopaedic Unit, National Haemophilia Centre, P.O. Box 66743, Plaza Las Américas, Caracas 1061 A, Venezuela*

## **S.M. Funk BS, PT**

*Mountain States Regional Hemophilia and Thrombosis Center, University of Colorado Health Sciences Center and The Children's Hospital, Denver, Colorado, PO Box 6507, Mail Stop F-416, Aurora, Colorado 80045-0507, USA*

## **J. Gago MD**

*Consultant Haematologist, Haemophilia Centre, La Paz University Hospital, Madrid, Spain*

## **G. Galatro MD**

*Orthopaedic Surgeon, Argentinian Haemophilia Foundation, Soler 3485, C.P. 1425, Buenos Aires, Argentina*

## **J. Galina MD**

*Department of Orthopedics, Mount Sinai Medical Center, New York, NY, USA*

## **M.S. Gilbert MD**

*Consultant Orthopedic Surgeon, Department of Orthopaedics, Mount Sinai Medical Center, New York, NY, USA*

## **N.J. Goddard MB, FRCS**

*Consultant Orthopaedic Surgeon, Department of Orthopaedics and Haemophilia Centre, Royal Free Hospital, London, UK*

## **J. Gracia MD**

*Haematologist, Haemophilia Centre, La Paz University Hospital, Madrid, Spain*

## CONTRIBUTORS

### L. Heijnen MD, PhD

*Consultant Rehabilitation Physician, Van Creveldkliniek University Medical Centre Utrecht and Rehabilitation Centre De Trappenberg, Huizen, Holland*

### M. Heim MB, ChB

*Professor, Department of Orthopaedics and Rehabilitation, Israel National Haemophilia Centre, Tel Hashomer Hospital, Israel 52621*

### P.J.M. Helders MD

*Consultant Paediatrician, Wilhelmina Children's Hospital, University Medical Centre, Division of Paediatrics, Department of Paediatric Physiotherapy, Rm. KB 02.056.0, Utrecht, Holland*

### F. Hernandez-Navarro MD

*Chairman, Service of Haematology, La Paz University Hospital, Madrid, Spain*

### I. Hvid MD

*Consultant Orthopaedic Surgeon, Aarhus University Hospital/Aarhus Kommunehospital, Department of Orthopaedic Surgery, Paediatric Orthopaedic Section, 44 Noerrebrogade, DK-8000 Aarhus C, Denmark*

### V. Jimenez-Yuste MD

*Haematologist, Haemophilia Centre, La Paz University Hospital, Madrid, Spain*

### R.F. Kilcoyne MD

*Professor Emeritus, Department of Radiology and Orthopedics, University of Colorado Health Sciences Centre, Denver, Colorado, USA*

### C.N. Kraft MD

*Orthopaedic Surgeon, Department of Orthopaedics, University of Bonn, D-53105 Bonn, Germany*

### C. Kramer MD

*Orthopaedic Surgeon, Department of Orthopaedics, University of Bonn, D-53105 Bonn, Germany*

### F.P.J.G. Lafeber PhD

*Vancreveldkliniek, National Haemophilia Treatment Centre, Department of Rheumatology and Clinical Immunology, University Medical Centre Utrecht, Utrecht, Holland*

### L. Lahaye MD

*Orthopaedic Surgeon, Department of Orthopaedics, University of Bonn, D-53105 Bonn, Germany*

### A. Llinas MD

*Consultant Orthopaedic Surgeon, Department of Orthopaedics, Fundación Santa Fé de Bogotá and Fundación Cosme y Damián, Bogotá, Colombia, Avenida 9 # 117-20, No. 811, Bogotá, Colombia*

### J.V. Luck Jr MD

*Chief of Orthopedics, Haemophilia Treatment Centre, Orthopedic Hospital, Los Angeles, CA; Professor and Executive Vice Chairman, UCLA-Orthopedic Hospital Department of Orthopedics, University of California at Los Angeles School of Medicine, Los Angeles, CA, USA*

### M.J. Manco-Johnson MD

*Mountain States Regional Hemophilia and Thrombosis Center, University of Colorado Health Sciences Center and The Children's Hospital, Denver, Colorado, PO Box 6507, Mail Stop F-416, Aurora, Colorado 80045-0507, USA*

### M. Marin-Ferrer MD

*Department of Nuclear Medicine, La Paz University Hospital, Madrid, Spain*

### L.M. Martin-Curto MD

*Department of Nuclear Medicine, La Paz University Hospital, Madrid, Spain*

### C. Martin-Hervas MD

*Consultant Radiologist, Department of Radiology, La Paz University Hospital, Madrid, Spain*

### C. Nicolay MD

*Institute for Medical Statistics, University of Bonn, Germany*

### R. Nuss MD

*Associate Professor, Department of Pediatrics, The Children Hospital, University of Colorado Health Sciences Centre, Denver, Colorado, USA*

### R. Perez-Bianco MD

*Consultant Haematologist, Argentinian Haemophilia Foundation, Soler 3485, C.P. 1425, Buenos Aires, Argentina*

### C.J. Petersson PhD

*Associate Professor, Department of Orthopaedics, Malmö University Hospital, SE 205 02-Malmö, Sweden*

### F. Querol MD

*Consultant Rehabilitation Specialist, Unit for Congenital Bleeding Disorders, La Fe University Hospital, Valencia; Lecturer, Department of Physiotherapy, University of Valencia, Spain*

### M. Quintana MD

*Consultant Haematologist, Haemophilia Centre, La Paz University Hospital, Madrid, Spain*

### J.A. Riera MD

*Chief, Spine and Pelvis Unit, Hospital, Santiago, Mutual de Seguridad, A.B. O'Higgins 4848, Santiago, Chile*

### E.C. Rodriguez-Merchan MD, PhD

*Consultant Orthopaedic Surgeon, Service of Traumatology and Orthopaedic Surgery, and Haemophilia Centre, La Paz University Hospital, Madrid, Spain*

### G. Roosendaal MD, PhD

*Van Creveldkliniek, National Haemophilia Treatment Centre, Division of Internal Medicine, University Medical Centre Utrecht, Utrecht, Holland*

### A. Saker MD

*Department of Orthopaedics, University of Bonn, D-53105, Bonn, Germany*



**S. Schulman MD**

*Consultant Haematologist, Coagulation Unit, Department of Haematology, Karolinska Hospital, S-171 76 Stockholm, Sweden*

**G. Schumpe MD**

*Department of Orthopaedics, University of Bonn, D-53105 Bonn, Germany*

**A. Seuser MD**

*Department of Orthopaedics, Kaiser Karl Clinic Bonn, Graurheindorferstr. 137, D-53117 Bonn, Germany*

**M. Silva MD**

*Orthopedic Surgeon, Research Fellow at Orthopedic Hospital, Los Angeles, California, USA*

**P.L. Solimeno MD**

*Consultant Orthopaedic Surgeon, 1st Orthopaedic Clinic, Hospital CTO, Via Bignami 1, Milan, Italy*

**N. Vatani MD**

*Argentinian Haemophilia Foundation, Soler 3485, C.P. 1425, Buenos Aires, Argentina*

**A. Villar MD**

*Consultant Haematologist, Haemophilia Centre, La Paz University Hospital, Madrid, Spain*

**R. Viso MD**

*First Assistant, Orthopaedic Unit, National Haemophilia Centre, Caracas, Venezuela*

**T. Wallny MD**

*Consultant Orthopaedic Surgeon, Department of Orthopaedics, University of Bonn, D-53105 Bonn, Germany*

**J.D. Wiedel MD**

*Professor, Anschutz Outpatient Pavilion, Department of Orthopedics, University of Colorado Health Sciences Centre, Box 6510, Mail Stop F-722, Aurora, CO 80045-0510, USA*

**J. York MD, FRACP, FRCP**

*Associate Professor and Consultant Emeritus, Department of Rheumatology, Institute of Rheumatology and Orthopaedics, The Royal Prince Alfred Hospital, Sydney, QEII Building, 59 Missenden Road, Camperdown NSW 2050, Australia*

# Preface

There are new perspectives in the treatment of intra-articular complications of haemophilia that I have tried to clarify in this book with the help of clinicians and academics who have a high degree of expertise in the field. The patient with haemophilia presents a particular challenge for those providing musculoskeletal care. Haemophilia is a lifelong inherited bleeding disorder characterized by spontaneous bleeding resulting in painful joint deformities.

Unfortunately 70% of those with haemophilia worldwide have no access to adequate haematological care. Many of those individuals are untreated, and therefore suffer enormously. Often, expert orthopaedic care cannot be provided to the haemophilia patient because of the constraint of lack of clotting factor provision for economic reasons.

In the so-called 'developed world', the availability of safe and effective clotting factor concentrate has enabled the orthopaedic surgeon to approach the patient with haemophilia with almost the same security as a patient without a bleeding disorder. The development of high-purity concentrates has enabled peri-operative delivery of clotting factor by continuous

infusion, giving added safety during the period of surgery and the possibility of more intensive physiotherapy and rehabilitation postoperatively. The newer recombinant clotting factor concentrates are particularly easy to deliver by continuous infusion.

Today, synoviortheses, synovectomies, joint debridements, tendon lengthenings, osteotomies, joint fusions, removals of osteophytes and haemophilic cysts, joint arthroplasties and other orthopaedic procedures can be performed to relieve pain. Furthermore, these procedures are now available for the patient with an inhibitor (alloantibodies against infused exogenous factor VIII or IX).

I have tried to provide an in-depth analysis of the new perspectives involved in the treatment of those with haemophilia, and I hope that this book will provide information that will be helpful for those treating the articular manifestations of haemophilia. My experience as Editor of this book has been rewarding and challenging. I am indebted to my colleagues who have contributed chapters.

Editor: E.C. Rodriguez-Merchan

**PART**

**1**

# **General principles**



# Orthopaedic surgery for persons with haemophilia: general principles

*E.C. Rodriguez-Merchan*

## Introduction

The management of orthopaedic problems in haemophiliacs requires a haematologist, whose function is to control haemostasis, an orthopaedist, physical therapist, orthotist and occupational therapist, all of whom concentrate on the preservation and restoration of function to the musculoskeletal system. The clinical severity of haemophilia is usually related to the plasma level of factor VIII or factor IX. Patients are classified as having mild, moderate or severe haemophilia depending on the level of the deficient factor, which can be > 5% of normal in mild cases and < 1% of normal in severe haemophilia. This is reflected in the frequency and causes of bleeding. Whereas a patient with mild haemophilia will bleed rarely, usually only after significant trauma or surgery, those with severe haemophilia may have several episodes per month, and typically bleed spontaneously as a result of minimal trauma or activities of daily living. Over 90% of bleeding episodes in haemophilic patients occur within the musculoskeletal system and, of these, 80% occur within the joints.

## Management of intra-articular bleeds

The vast majority of bleeding episodes in haemophiliacs occur within the joints (haemarthrosis). Of these haemorrhages, the ankles, elbows and knees account for almost 80%. The involved articulation is usually held in flexion, and active and passive motion is painful and very restricted. With the early provision of the missing coagulation factor, haemorrhages can be controlled and conservative orthopaedic management can usually terminate the episode without any long-term complications.

Should the haemorrhage persist or a re-bleed occur, the synovium begins to hypertrophy (Fig. 1.1) and a vicious circle of chronic synovitis develops, leading to joint destruction and classical osteoarthropathy. The hypertrophic synovium is characterized by villous formation, markedly increased vascularity and the chronic presence of inflammatory cells. Synovitis causes hypertrophy of the epiphyseal growth plates [1].

Bone hypertrophy may lead to leg length discrepancies, angular deformities and alterations of contour in the developing skeleton.

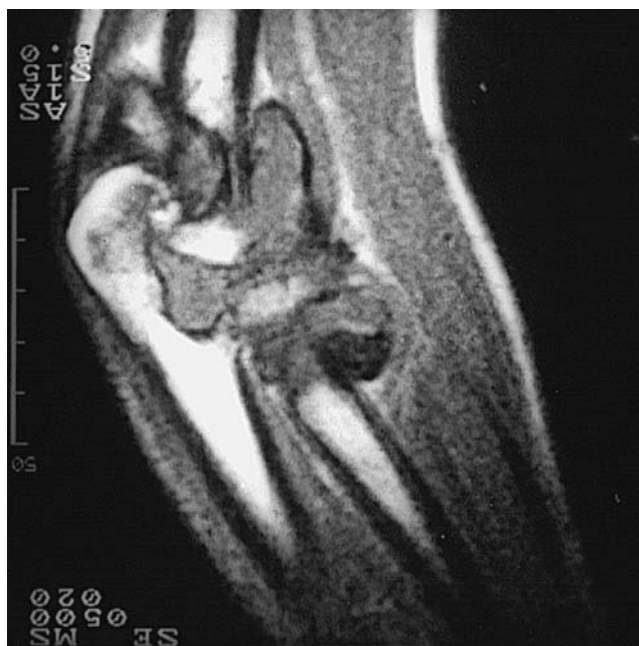

Fig. 1.1 Magnetic resonance imaging (MRI) scan of an elbow showing a severe degree of chronic haemophilic synovitis.

If the synovitis is not controlled, cartilage damage will follow. The synoviocytes disintegrate and release lysosomal enzymes, which not only destroy articular cartilage but also further inflame the synovial tissue. Blood breakdown products also affect the chondrocytes. The haemosiderin staining of the synovium and cartilage bears testimony to the destructive elements of proteolytic enzymes. Symptoms of chronic arthropathy typically develop by the second or third decade. As the joint cartilage progressively degrades, deterioration in joint function occurs.

## Continuous prophylactic clotting factor replacement (prophylactic therapy)

Prophylactic therapy has been reported to slow the natural course of haemophilic arthropathy. Swedish authors were the first to report that continuous prophylaxis from ages 2 to 18 years prevented the development of haemophilic arthropathy if

the concentration of the patient's deficient factor was prevented from falling below 1% of normal [2]. This can be achieved with administration of 25–40 units/kg factor VIII three times weekly in patients with haemophilia A and 25–40 units/kg factor IX twice weekly in patients with haemophilia B.

### Management of haemarthroses

If prophylactic therapy is not feasible because of expense or lack of venous access, then a major haemarthrosis must be aggressively treated to prevent progression to synovitis, recurrent joint bleeds and, ultimately, end-stage arthritis. These joint bleeds need the following:

- 1 transfusion to 50%;
- 2 aspiration (arthrocentesis) to debulk the joint blood;
- 3 short-term splinting for 48 h; and
- 4 transfusion every 48 h until the joint is fully rehabilitated and there is no evidence of synovitis. This requires 10–30 days of transfusion.

### Management of synovitis

If left untreated, synovitis followed by degenerative changes within the joint will occur and a stiff or painful joint will result. Both surgical synovectomy and radioactive synoviorthesis are procedures for synovial destruction used in a number of haemophilia centres for the management of chronic haemophilic synovitis. Taking into account the risk of infection after surgical procedures in human immunodeficiency virus (HIV) positive patients, synoviorthesis is recommended first. Radioactive synoviorthesis is also of particular interest in patients with haemophilia caused by factor inhibitors, who otherwise are difficult to treat. No complication related to radiation synovectomy has been reported to date. For the treatment of chronic haemophilic synovitis, synoviorthesis should always be indicated as the first procedure. It is an easy procedure with a number of satisfactory results [3].

With  $^{198}\text{Au}$  synoviorthesis there is an expected 75% success rate, while with  $^{90}\text{Y}$  synoviorthesis there is an expected 85% or more success rate. It is important to emphasize that no more than three synoviortheses can be repeated with a 3-month interval between them. If, after three procedures, synoviorthesis fails, a surgical synovectomy is indicated. Rifampicin is expected to produce similar results to  $^{90}\text{Y}$  in the small joints (elbows and ankles), but several weekly, painful injections are needed; in addition, rifampicin synoviorthesis is not recommended for the knee joint. Surgical synovectomy generally achieves similar results to  $^{90}\text{Y}$  synoviorthesis; however, as it is a surgical procedure under general anaesthesia, it is accompanied by a certain number of complications common to surgical procedures.

When surgical synovectomy is indicated for the knee, arthroscopic synovectomy is recommended because of the lower risk of infection and lack of postoperative mobility; however, there are no true comparative studies to conclude which type of

synovectomy is most efficient. For the elbows and ankles, open surgical synovectomy is advised. It is possible that the way forward is to use radioactive synoviorthesis ( $^{90}\text{Y}$  or  $^{32}\text{P}$ ) first, and then up to three times. If this fails for the knee, then arthroscopic synovectomy is indicated. Open surgical synovectomy for the knee should be the method of last resort, after three previous failures with the other procedures. Although difficulties arise when comparing different studies regarding synovitis of the knee, the decreased frequency of haemarthrosis after synoviorthesis is not as great as after operative synovectomy.

From the point of view of quality of life and economy, radioactive synoviorthesis offers advantages in that it is usually almost painless and requires minimum replacement therapy. Open surgical synovectomy of the knee in haemophilic patients who are managed with conventional postoperative therapy has frequently been complicated by a loss of motion, even with prolonged inpatient treatment. Rehabilitation after synovectomy of the knee is particularly difficult for children with haemophilia because they tend to be less motivated and co-operate less with the postoperative physical therapy programme. The rationale behind arthroscopic synovectomy of the knee in haemophilia is to provide a similar decrease in bleeding episodes as open synovectomy, while avoiding the loss of range of motion that can occur.

Personal experience and the general recommendation among orthopaedic surgeons and haematologists is that when three early consecutive synoviortheses (repeated every 3 months) fail to halt synovitis, a surgical synovectomy (open or by arthroscopy) should be immediately considered. Although patients are admitted to hospital for synoviorthesis for haematological preparation, it must be recognized that it is not necessary in every case and the procedure could be performed at the outpatient clinic with minimal risks. Radioactive synoviorthesis should be performed in very young patients, when the amount of synovial membrane is still moderate. Once the degree of synovitis has become severe, the expected results of synoviorthesis are decreased.

### Management of flexion contractures (tendon lengthening, extension osteotomy and external fixators)

In those patients with flexion contractures of the knee or ankle, provided the joints are preserved (without haemophilic arthropathy), it is advisable to carry out a tendon lengthening procedure in order to obtain adequate joint extension and to improve articular function. The most frequent tendon lengthening classically performed on haemophiliacs are Z-lengthening of the Achilles tendon (to correct equinus of the foot) and the so-called hamstrings release (commonly associated with a posterior capsulotomy) for flexion contractures of the knee.

At the knee, extension supracondylar osteotomy can be used to correct a fixed-knee flexion contracture. It is a major procedure which requires fracturing the femur at its supracondylar

area and then performing bone fixation by means of an adequate internal fixation device. External fixators can not only be used for fixation of fractures, such as those at the distal radius, but also for the treatment of flexion contractures. The aim is to obtain a progressive but efficient straightening of the affected joint, the most common being the circular fixator of Ilizarov.

The implantation of an external fixator is a rather complicated procedure, especially regarding its postoperative care. It has an extension device that allows an extension of 1°/day, up to a maximum of about 30°. Later on, in a second surgical procedure, the external fixator is removed and an orthosis is indicated in order to maintain the extension gained during the procedure. In other words, what an external fixator achieves is a slow but progressive extension of the soft tissues (including tendons, nerves and vessels). An excessively rapid extension will cause nerve paralysis, such as of the peroneal nerve at the knee. These procedures must be carried out when the contractures are only moderate and after the failure of conservative treatment. At the knee, such a conservative treatment entails the use of an extension traction followed by an orthosis of progressive extension together with a rehabilitation programme.

## Management of haemophilic arthropathy

### General principles

The orthopaedic complications of haemophilia are patient-specific and treatment protocols often need to be tailored to suit the individual. There are a number of orthopaedic procedures that can be carried out in haemophilic joints when a severe degree of arthropathy is reached.

#### *Curettage of subchondral bone cysts and cheilectomy*

Some haemophilic patients present with large subchondral cysts on the humeral head or the proximal tibia. When such cysts are symptomatic, curettage and filling with fibrin glue and/or cancellous bone graft is recommended. Other patients present with an anterior osteophyte at the distal tibia (ankle joint) that elicits pain at foot dorsiflexion and when walking. Under such circumstances the surgical removal of the osteophyte (cheilectomy) is indicated. It is commonly performed by open surgery although it can also be carried out by arthroscopy.

#### *Joint débridement*

Joint débridement is commonly performed on young patients with severe haemophilic arthropathy of the knee, in patients who the orthopaedic surgeon in charge considers are too young to indicate a total joint replacement. In other words, débridement is a procedure that can alleviate articular pain and bleeding for a number of years and delays the need for a total joint arthroplasty. Joint débridement consists of opening the joint in order to remove existing osteophytes, resect the synovium

and carry out curettage of the articular cartilage of femoral condyles, tibial plateaus and patella.

Some authors do not believe in the efficacy of débridement and so when facing a severe degree of arthropathy in a young patient they directly indicate a total knee replacement. It should be emphasized that if débridement fails, a joint arthroplasty can be performed by the same approach. Some authors perform joint débridement by arthroscopic means with similar results to open surgery. Often, a synovectomy and débridement are performed together because haemophilic synovitis and early arthropathy commonly coexist. Again, postoperative rehabilitation is paramount to avoid loss of range of motion, and therefore should be associated with adequate haematological control in order to avoid re-bleedings.

#### *Realignment osteotomy*

Sometimes, during childhood, adolescence or early adulthood, haemophilic joints undergo an alteration of their normal axis. Knees show varus, valgus and flexion deformities, and something similar may occur at the ankle joint. When the malaligned joint is painful, the patient needs an alignment osteotomy. The most common osteotomies performed in haemophiliacs are: proximal tibial valgus osteotomy, supracondylar femoral varus osteotomy, ankle alignment osteotomy and knee extension osteotomy.

In all of these the rationale is to produce a fracture at an adequate place in order to re-align the joint to a normal axis. After the osteotomy it is necessary to obtain an adequate bone fixation by any kind of internal fixation device. (I have sometimes corrected a flexion contracture of the knee at the same time as a spontaneous supracondylar fracture of the femur.) When axial malalignment occurs in a joint with severe haemophilic arthropathy, a total joint arthroplasty is usually indicated and hence both problems can be solved at the same time.

#### *Arthrodesis*

Joint fusion (arthrodesis) is today used only at the ankle. It is indicated when a severe ankle arthropathy causes intense pain and/or disability, ankle arthroplasty being the alternative. However, ankle replacement has not been proved to be better than arthrodesis (not only in haemophiliacs). Ankle arthrodesis usually requires two approaches in order to remove the involved cartilaginous surfaces of distal tibia and talus. Then it is necessary to compress the surfaces using lag screws, staples or an external fixator. By 10–12 weeks joint fusion is usually achieved and hence all immobilization devices can be removed. Ankle pain is likely to disappear although subtalar pain sometimes appears after arthrodesis. Such pain is a result of the abnormal biomechanics of the foot after ankle fusion. In summary, ankle arthrodesis is an extreme surgical procedure which considerably improves joint pain but sometimes provokes another type of pain, usually not so intense as the primary one.

*Joint prosthesis*

The most common total joint replacements performed in adult haemophilic patients are at the hip and at the knee, and they are indicated when pain and disability are intense. Hip arthropathy causes pain at the groin which can irradiate to the ipsilateral knee. Sometimes it is advisable to perform two or three surgical procedures in a single surgical session in order to maximize the whole function of the affected limbs. Alternatively, it is possible to operate on the most painful joint first and then treat the others (3–6 months later). Shoulder and elbow arthroplasties have been rarely used in haemophilia because their results have not been as successful as those obtained in hips and knees.

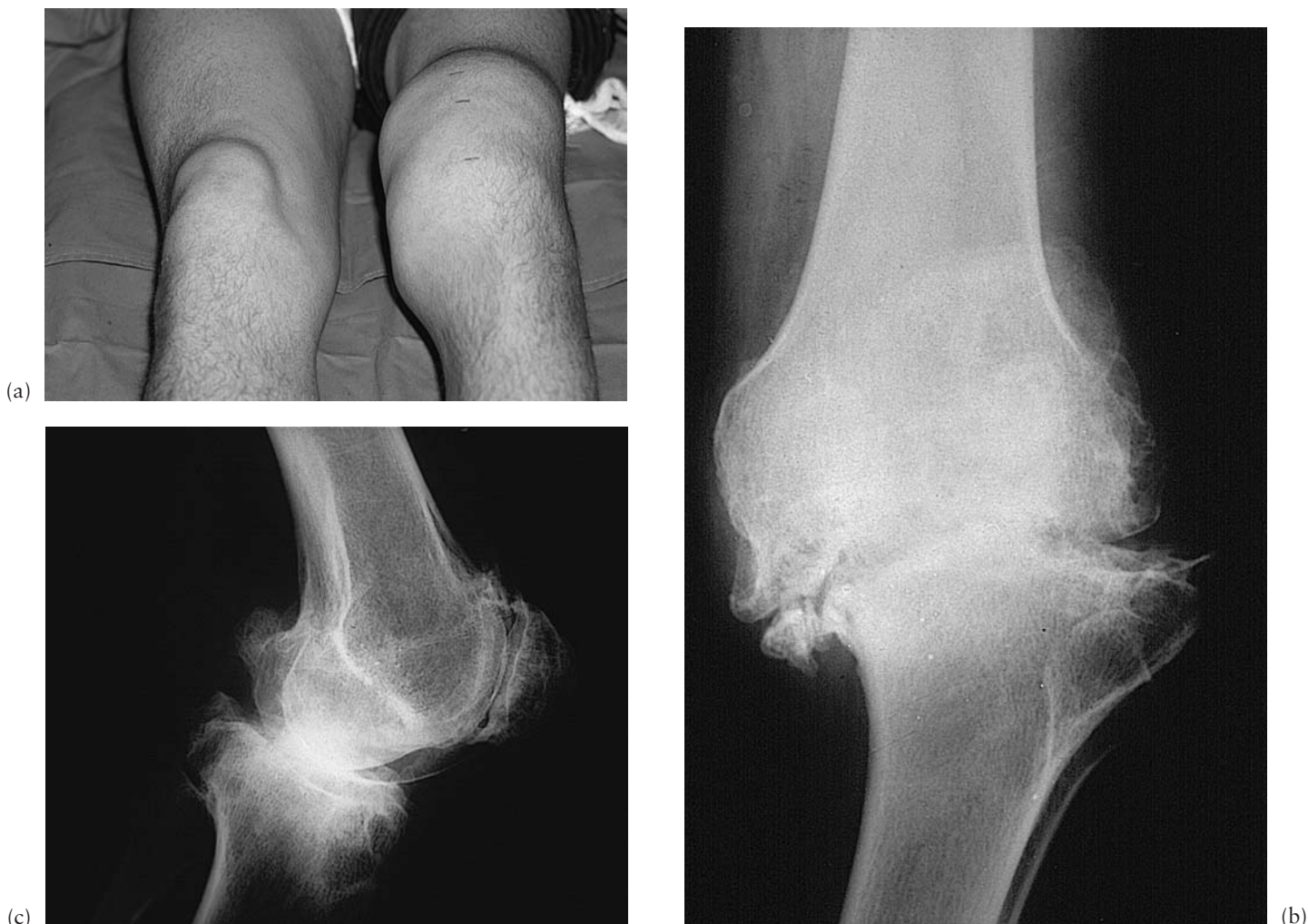*Total knee replacement*

Most total knee arthroplasties (TKAs) are versions of a total condylar arthroplasty. The surgical procedure is commonly performed under ischaemia through a straight anterior incision

and a parapatellar medial approach. It is carried out with the help of intra- and extramedullary guides, which facilitate adequate bone cuts on distal femur and proximal tibia; these cuts are needed for the implantation of the prosthetic components, using bone cement. Both cruciate ligaments (anterior and posterior) are usually removed during the operation. After the implantation of the prosthesis, the tourniquet is released in order to carry out meticulous haemostasis. The results obtained with TKA in haemophilia are quite satisfactory so far, which is why a prosthesis is considered to be a good procedure in severe cases of knee haemophilic arthropathy (Fig. 1.2).

*Total hip replacement*

Although there are a number of prosthetic models (cemented and cementless), the most commonly used is Charnley's cemented low-friction arthroplasty. The indications for a total hip arthroplasty are intense groin pain (sometimes irradiating



**Fig. 1.2** Total knee arthroplasty for severe haemophilic arthropathy of the left knee of a 20-year-old patient. Arthropathy developed after 20 years of uncontrolled haemophilic synovitis: (a) clinical view of the synovitis; (b) Anteroposterior (AP) preoperative radiograph at the age of 40; (c) lateral preoperative view;



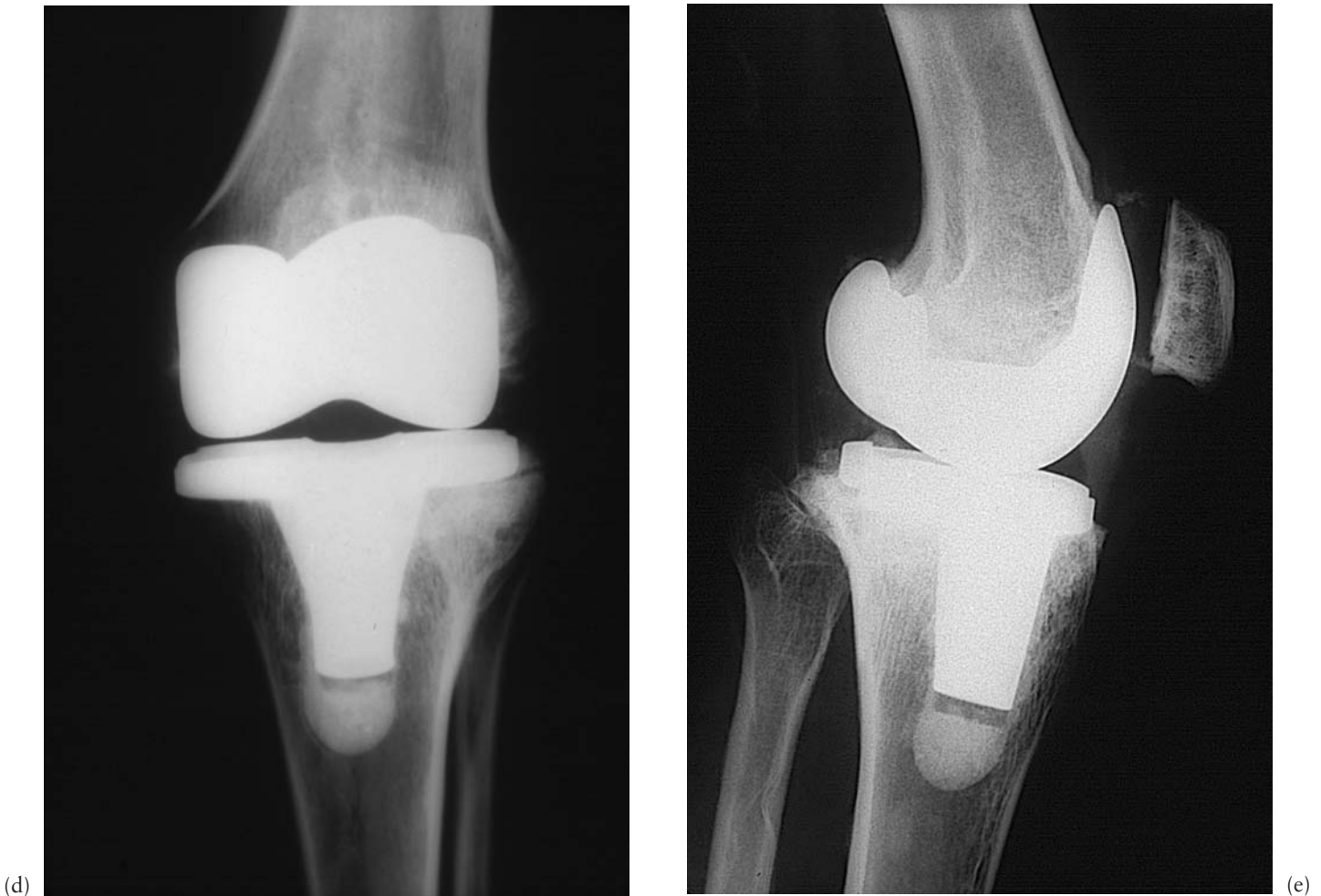


Fig. 1.2 (cont'd) (d) AP radiograph at 5 years; and (e) lateral view at 5 years. The result was excellent.

to the ipsilateral knee) associated with advanced haemophilic arthropathy. There are a number of surgical approaches, but the most commonly used are the lateral and the posterior approaches. During the surgical procedure the acetabulum has to be reamed before the implantation of the acetabular component, the femoral head has to be removed and the femoral canal prepared for the implantation of the femoral stem. Published results have been highly satisfactory in haemophilia.

#### Anatomical considerations

##### *Shoulder arthropathy*

Growth disturbance of the epiphysis may cause a small atrophic humeral head with a varus deformity. In the mature shoulder, osteophyte formation may be pronounced. Arthrodesis of the shoulder has proved to be a good and reliable procedure. However, in haemophiliacs, where elbow joint destruction and limitation of movement are common, this procedure must be

more critically reviewed. Total joint arthroplasty remains controversial.

##### *Elbow arthropathy*

Because of the severe valgus deformity that many haemophilic patients have at the elbow, the ulnar nerve can be overstretched. Such a problem is usually detected early because of the typical paraesthesias that are encountered at the fourth and fifth fingers. Diagnosis is confirmed by means of an electromyogram (EMG), which defines whether the involvement is a neurapraxia, neurotmesis or axonotmesis: that is to say, whether the involvement is reversible, partially reversible or irreversible, respectively. The surgical procedure consists of the release of the ulnar nerve from the sulcus where it normally runs (neurolysis). It is a relatively simple procedure with a high rate of satisfactory results, provided that the lesion is reversible.

Ishiguro *et al.* [4] investigated the characteristics of haemophilic arthropathy of the elbow joint in 32 patients aged 5–12 years

who had been followed from infancy. There was a discrepancy between the growth of the intra-articular subchondral epiphyseal cartilage and the cartilage of the medial and lateral epicondyles (apophyseal cartilage). This differential growth may be an important factor in the development of complicated and variable haemophilic elbow deformities. As this joint may prove to be problematic, the surgical options are greatly reduced.

Excision of the radial head and partial open synovectomy is a consistently reliable operation, which appears to prolong the functional life of the elbow joint. With proper selection it dramatically reduces the rate of haemarthroses, improves forearm pronosupination by 20–60°, decreases pain, improves function and does not cause elbow instability. The use of total elbow joint replacement is not yet an accepted form of therapy, and so two options remain: the use of an orthotic brace or arthrodesis.

#### *Hip arthropathy*

Fortunately, bleeds into the hip joint are uncommon. However, they carry the added risk of developing avascular necrosis. Haemorrhages in the growing hip may result in changes similar to Perthes' disease. To reduce the risk of avascular necrosis, these patients should have the hip joint aspirated. End-stage haemophilic arthropathy necessitating arthroplasty is infrequent in the hip. Although results are inferior to those obtained in arthrosis, total hip replacement should be considered in haemophiliacs. Kelley *et al.* [5] reported a high rate of loosening of cemented hip prostheses in patients with haemophilia. There was also a high overall rate of mortality and a high rate of late deep infection in patients who were seropositive for HIV.

#### *Knee arthropathy*

Smith *et al.* [6] proposed that angular deformities in the lower limbs placed a varus or valgus strain on the knee joint, and that this malalignment was the trigger for haemarthroses. Based upon this theory, osteotomies were carried out on the long bones. Arthrodesis of a knee joint is a relatively simple procedure, but haemophilia is a systemic disorder and not just a regional knee pathology. Therefore, one must take into account that the ankle joint distal to the arthrodesed knee or the hip proximal to that knee may become equally pathological, and a double arthrodesis in the same limb makes ambulation extremely difficult. However, total joint replacements in relatively young patients hold intrinsic dangers of prosthesis loosening and late joint infections in immunologically compromised persons. Débridement should be considered in the young haemophiliac to avoid or delay TKA. The operation may give the patient years of life without pain.

The primary goals of TKA are to relieve pain, restore function and achieve stability. In chronic haemophilic arthropathy the operation is technically demanding because of soft-tissue fibrosis, flexion contractures and poor quality of the bone. For

these reasons, complications other than infection in HIV-negative haemophilia are more prevalent than in osteoarthritis. Moreover, if the patient is HIV-positive with a CD4 count of < 200/mm<sup>3</sup>, the risk of postoperative infection after TKA can reach up to 30%.

In the era of total joint replacement, a TKA should be indicated in HIV-positive patients with haemophilia who have severe pain in the knee and disability. However, the high risk of infection and other postoperative complications is a concern. It should not be inferred that a TKA should be avoided in a HIV-positive patient with haemophilia, but that the orthopaedic surgeon should weigh the risks and benefits. A careful and conservative approach is needed. However, recent improvements in medical treatment can diminish the previously reported rate of postoperative infection and give grounds for continued optimism.

#### *Ankle arthropathy*

The most common deformities associated with ankle and subtalar arthropathy are fixed plantar flexion, usually as a result of anterior changes; varus hindfoot, which suggests subtalar involvement; and valgus at the ankle. The non-operative management of ankle arthropathy includes splints, support shoes or boots, wedge insoles and calipers. Supramalleolar varus osteotomy has been reported for haemophilic arthropathy and secondary valgus deformity. The procedure is an attractive alternative to the more commonly used surgical option of arthrodesis [7].

## **Management of intra-muscular bleeds**

In the majority of cases, bleeds within muscles are caused by trauma. They are very often associated with direct trauma and the pathology becomes quite evident because of the swelling, pain, local warmth and bruising that typically appear in the overlying skin. The vast majority of these muscle bleeds resolve spontaneously, leaving no functional loss. However, it is necessary to examine the patient carefully to ensure that there is no danger to vascular elements or neural compromise.

The muscles in the forearm and the shin are enclosed in tight fascial compartments, and even relatively small bleeds can cause a large rise in pressure in the intracompartmental space. Volkmann's contracture of the hand and foot have been reported as a result of such bleeding incidences within the closed compartments. The treatment may be of a conservative nature wherein haemostasis is established, the limb rested in elevation, analgesia provided and, as the swelling subsides, there is a decrease in pain and a gradual return to function.

Should the pressure be very high, decompression is vital. This decompression may be effected either by drainage of the haematoma or by formal surgery and incision of the fascial envelope. The most common and most serious of muscle bleeds occur in the iliopsoas muscle. Lower quadrant abdominal pain can mimic the symptomatology of an acute appendicitis. Compression of the femoral nerve may present as an area of reduced

sensation in the anterior aspect of the thigh. Attempts to extend the hip joint cause severe pain and force the patient into hyperlordosis of the lumbar spine.

As it is difficult clinically to differentiate between a bleed into the iliopsoas muscle and an intra-articular haemorrhage into the hip joint, one must rely on objective testing. Ultrasound can differentiate between the largely extended joint capsule with intra-articular haemorrhage and the bleed that is situated within the muscle fibres. The iliopsoas bleed takes a long time to improve, and the flexion contracture of the hip joint may persist for weeks. Secondary haemorrhages into the same area are common and so prophylactic factor replacement is advised. Whereas coxhaemarthrosis is a problem costing days of extra treatment, an iliopsoas haematoma may require weeks until full recovery is achieved.

## Management of haemophilic cysts

The haemophilic cyst (pseudotumour) is basically an encapsulated haematoma. A thick fibrous capsule surrounds a haematoma in varying degrees of organization; calcification and ossification may be seen within it. Proximal haemophilic cysts occur in the proximal skeleton, especially around the femur and pelvis. They appear to originate in the soft tissue, erode bone secondarily from outside and develop slowly over many years. Haemophilic cysts occur in adults and do not respond to conservative treatment. Large proximal cysts in adults should be removed surgically as soon as they are diagnosed. Cysts occurring distal to the wrist and ankle appear to be secondary to intraosseous haemorrhage and develop rapidly. They are seen mainly in children and adolescents. Distal haemophilic cysts should be treated primarily with long-term replacement therapy and cast immobilization. In children, surgical removal or even amputation is indicated when conservative management fails to prevent progression. Percutaneous evacuation should be considered in inoperable advanced haemophilic cysts. Evacuation is carried out with a large trocar under image intensifier control; the cavity is filled with different quantities of fibrin seal or cancellous bone, depending on the size of the cyst.

The management of the patient with a haemophilic cyst is complex and with a high rate of potential complications. There are a number of therapeutic alternatives for this dangerous condition: embolization, radiation, percutaneous management, surgical removal and exeresis and filling of the dead cavity. It is hoped that with the advent of widespread maintenance therapy, haemophilic cysts will be less common in the future. It is important that they are diagnosed early, and prevention of muscular haematomas is key to reducing their incidence. Untreated, proximal haemophilic cysts will ultimately destroy soft tissues, erode bone and may produce neurovascular complications. Surgical excision is the treatment of choice but should only be carried out in major haemophilia centres by a multidisciplinary surgical team [8].

## Management of fractures in haemophiliacs

The goal of modern fracture treatment is to obtain an optimal outcome with the patient's return to full activity as soon as possible. Today, internal stabilization is indicated in most displaced fractures in the adult, whereas external fixation remains the best choice for initial stabilization with severe soft-tissue injuries. If a fracture is correctly treated in a haemophilic patient it will progress to consolidation in a similar time frame to those occurring in the general population [9].

The incidence of fracture in patients with haemophilia is controversial but, in our experience, it is infrequent because, understanding the gravity of their illness, these individuals are less ambulant so their daily activities are reduced because of associated arthropathy and contractures. However, poor musculature, osteoporosis and haemophilic changes in the bone may predispose them to risk of fractures. In patients with haemophilia fracture can occur after a trivial trauma, especially if associated factors of haemophilic arthropathy, muscle wasting and osteoporosis render the bone more fragile and prone to fracture. The bone may have structural changes secondary to subperiosteal or intraosseous bleeding producing haemophilic cysts.

Fractures can occur anywhere in the long bones but are more prevalent near the joints or in the diaphysis of the long bones. The lower limb bones, and especially the femur, are the most common site of fracture. Clinically, the symptoms of fractures are no different from those of non-haemophiliacs but the haematomas tend to be large in volume and may be the cause of acute compartment syndrome. Compartment syndrome is a condition characterized by raised pressure within a closed space with the potential to cause irreversible damage to the contents of the closed space. The surgeon must have a thorough knowledge of the surgical anatomy of the upper and lower extremities to perform adequate decompression under emergency conditions. If early treatment is better than late treatment, prevention must be better still. The only effective way to decompress an acute compartment syndrome is by surgical fasciotomy.

## Risks of operating on an HIV-positive haemophilic patient

Haemophilic patients infected by the HIV virus are at risk of bacterial and opportunistic infection because of worsening immunodepression. In these patients, the risk of infection after orthopaedic surgery is of considerable concern [10]. A survey of haemophilia treatment centres in the USA by Ragni *et al.* [11] determined the incidence of postoperative infection in HIV-positive haemophilic patients with CD4 counts of 200/mm<sup>3</sup> or less. Of 66 patients undergoing 74 orthopaedic procedures, postoperative infection occurred in 10 patients (13%) up to 5 months postoperatively. *Staphylococcus aureus* was the most common organism (60%), and the knee was the most

commonly affected joint (90%). Arthroplasty appeared to have 10 times the risk of infection than other procedures. The risk of late infection of a total joint arthroplasty is higher, but when a patient is suffering incapacitating pain, the resulting improvement in their quality of life certainly warrants the procedure, provided the patient is fully informed about the surgery and its risks [12,13].

## Orthopaedic surgery in haemophilic patients with inhibitors

The development of an inhibitor against factor VIII or factor IX is the most common and most serious complication of replacement therapy in patients with haemophilia A or B, resulting from the exclusive use of virus-inactivated plasma-derived concentrates or recombinant products. When present, the inhibitor inactivates the biological activity of infused factor VIII or factor IX, making the patient refractory to treatment. Between 10 and 30% of patients with severe haemophilia A, and 2–5% of patients with severe haemophilia B or mild/moderate haemophilia A, develop an inhibitor against factor VIII or factor IX after treatment with either plasma-derived or recombinant products. Inhibitor detection using the Bethesda assay, measured in Bethesda units (BU), is part of the regular follow-up for all haemophilic patients treated with such products. After the development of the inhibitor, the inhibitor titre decreases if no factor VIII- or factor IX-containing products are used for a long period so that the inhibitor may become undetectable. However, the inhibitor usually reappears after a new challenge with factor VIII- or factor IX-containing products (anamnesic response).

The author's experience and a review of the literature on inhibitors have shown that, with the availability of FEIBA® and recombinant activated factor VII (rFVIIa), haemophilic patients with high inhibitor titres requiring elective orthopaedic surgery can undergo such surgery with a high expectation of success [14–16]. The advent of rFVIIa has made major elective orthopaedic surgery possible in haemophilia patients with high-titre inhibitors, leading to an improved quality of life for these patients. Recombinant FVIIa and FEIBA® appear to be efficient haemostatic product for surgery in patients suffering from haemophilia A and B with inhibitors. Thorough analysis of each case as part of a multidisciplinary team will allow us to perform elective orthopaedic procedures in patients with inhibitors [16].

## Conclusions

The orthopaedic problems of haemophilia and the surgical techniques most frequently performed by orthopaedic surgeons for haemophilia patients are summarized in Table 1.1. Sometimes it is recommended to carry out two or three orthopaedic surgical procedures in a single operative session, with the aim of solving the functional problem in a more global way, which

**Table 1.1** Main orthopaedic complications of haemophilia and their recommended solutions.

- 
- 1 Haemarthrosis: aspiration (arthrocentesis)
  - 2 Chronic synovitis: radiosynoviorthesis and surgical synovectomy
  - 3 Fixed-joint flexion contractures: tendon lengthening, external fixators and extension osteotomy
  - 4 Arthropathy: ulnar nerve release, cheilectomy, curettage of bone cysts, joint débridement, alignment osteotomy, arthrodesis and total joint arthroplasty
  - 5 Haematomas and haemophilic cysts: opening of compartment syndromes and removal of cysts (pseudotumours)
  - 6 Fractures: bone stabilization by closed or open methods
- 

usually is polyarticular. There is no doubt that this involves a greater anaesthetic risk, but avoids the repetition of surgical procedures and reduces factor consumption.

Close co-operation between haematologists, orthopaedic surgeons, rehabilitation physicians, paediatricians, psychologists, physiotherapists and nurses is paramount for the satisfactory outcome of all orthopaedic surgical procedures described in this chapter. There is no doubt that continuous prophylactic clotting factor replacement (prophylactic therapy) is the way to avoid the orthopaedic problems of haemophilia that can still be seen today. Until such a goal can be realized, the orthopaedic surgeon must continue to perform arthrocentesis, synoviorthesis, synovectomy, tendon lengthening, débridement, osteotomy, joint replacement, osteosynthesis of fractures and other less frequent surgical procedures for persons with haemophilia. The chapters that follow analyse new perspectives in the treatment of haemophilic joints.

## References

- 1 Rodriguez-Merchan EC. Effects of haemophilia on articulations of children and adults. *Clin Orthop* 1996; **328**: 7–13.
- 2 Nilsson IM, Berntorp E, Löfqvist T, Pettersson H. Twenty-five years experience of prophylactic treatment in severe haemophilia A and B. *J Intern Med* 1992; **232**: 25–32.
- 3 Rodriguez-Merchan EC. Methods to treat chronic haemophilic synovitis. *Haemophilia* 2001; **7**: 1–5.
- 4 Ishiguro N, Yasuo S, Takamatu S, Iwata H. Hemophilic arthropathy of the elbow. *J Pediatr Orthop* 1995; **15**: 821–5.
- 5 Kelley SS, Lachiewicz PF, Gilbert MS, Bolander ME, Jankiewicz JJ. Hip arthroplasty in haemophilic arthropathy. *J Bone Joint Surg Am* 1995; **77-A**: 828–34.
- 6 Smith MA, Urquhart DR, Savidge GF. The surgical management of varus deformity in haemophilic arthropathy of the knee. *J Bone Joint Surg Br* 1981; **63-B**: 261–5.
- 7 Pearce MS, Smith MA, Savidge GF. Supramalleolar osteotomy for haemophilic arthropathy of the ankle. *J Bone Joint Surg Br* 1994; **76-B**: 947–50.
- 8 Rodriguez-Merchan EC. Haemophilic cysts (pseudotumours). *Haemophilia* 2002; **8**: 393–401.
- 9 Rodriguez-Merchan EC. Bone fractures in the haemophilic patient. *Haemophilia* 2002; **8**: 104–11.

- 10 Rodriguez-Merchan EC. Management of the orthopaedic complications of haemophilia. *J Bone Joint Surg Br* 1998; **80-B**: 191–6.
- 11 Ragni MV, Crossett LS, Herndon JH. Postoperative infection following orthopaedic surgery in human immunodeficiency virus-infected haemophiliacs with CD4 counts  $\leq 200/\text{mm}^3$ . *J Arthroplasty* 1995; **10**: 716–21.
- 12 Rodriguez-Merchan EC, Goddard NJ, Lee CA. *Musculoskeletal Aspects of Haemophilia*. Oxford: Blackwell, 2000.
- 13 Rodriguez-Merchan EC. Total knee arthroplasty in patients with haemophilia who are HIV-positive. *J Bone Joint Surg Br* 2002; **84-B**: 170–2.
- 14 Rodriguez-Merchan EC, de la Corte H. Orthopaedic surgery in haemophilic patients with inhibitors: a review of the literature. In: Rodriguez-Merchan EC, Goddard NJ, Lee CA, eds. *Musculoskeletal Aspects of Haemophilia*. Oxford: Blackwell Publishing, 2000: 136–42.
- 15 Rodriguez-Merchan EC, Lee CA. *Inhibitors in Patients with Haemophilia*. Oxford: Blackwell, 2002.
- 16 Hvid I, Rodriguez-Merchan EC. Orthopaedic surgery in haemophilia patients with inhibitors: an overview. *Haemophilia* 2002; **8**: 288–91.