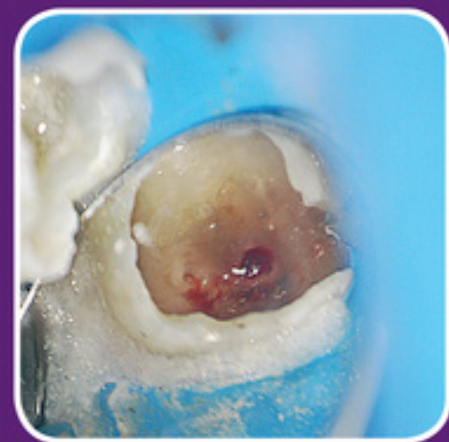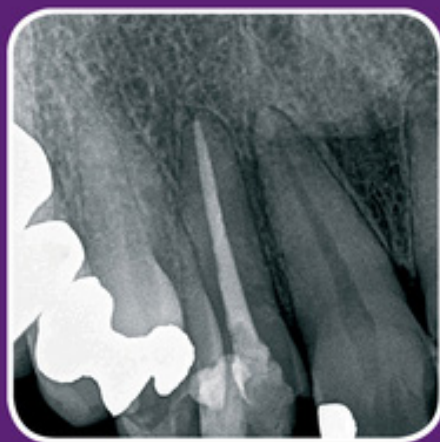
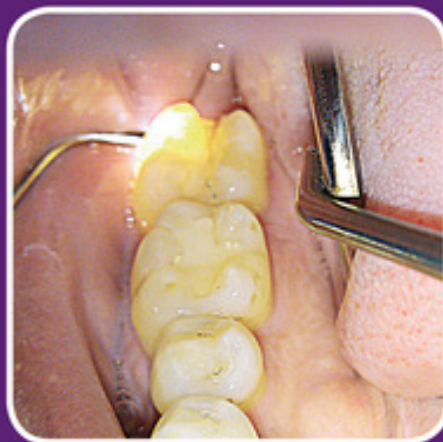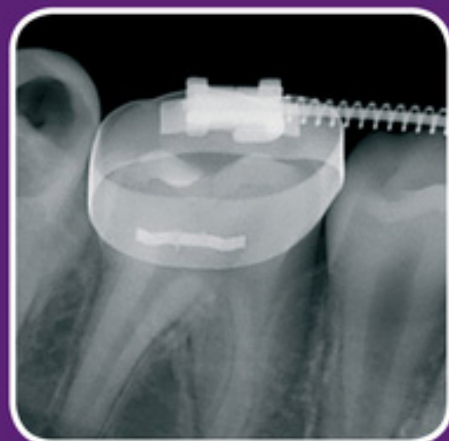


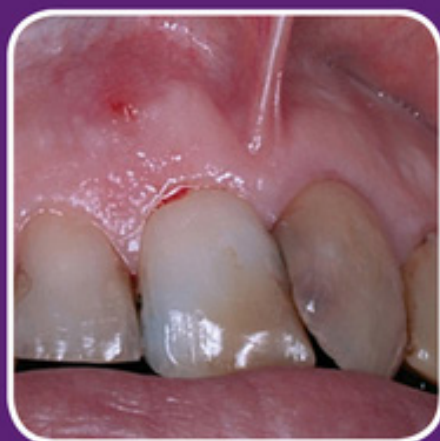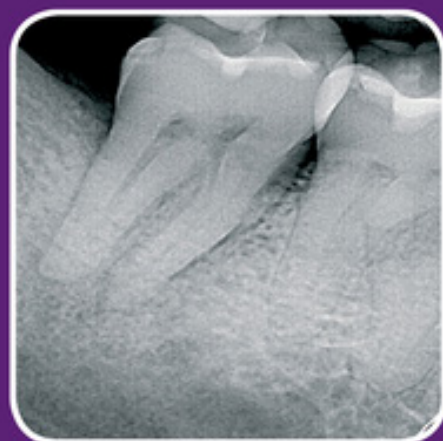CLINICAL CASES SERIES

Clinical Cases in Endodontics

Takashi Komabayashi



WILEY Blackwell

Clinical Cases in Endodontics

Clinical Cases Series

Wiley-Blackwell's Clinical Cases series is designed to recognize the centrality of clinical cases to the dental profession by providing actual cases with an academic backbone. This unique approach supports the new trend in case-based and problem-based learning. Highly illustrated in full color, the Clinical Cases series utilizes a format that fosters independent learning and prepares the reader for case-based examinations.

Clinical Cases in Endodontics

by Takashi Komabayashi (Editor)

Clinical Cases in Orofacial Pain

by Malin Ernberg, Per Alstergren

Clinical Cases in Implant Dentistry

by Nadeem Karimbux (Editor), Hans-Peter Weber (Editor)

Clinical Cases in Orthodontics

by Martyn T. Cobourne, Padhraig S. Fleming, Andrew T. DiBiase, Sofia Ahmad

Clinical Cases in Pediatric Dentistry

by Amr M. Moursi (Editor), Marcio A. da Fonseca (Assistant Editor), Amy L. Truesdale (Associate Editor)

Clinical Cases in Periodontics

by Nadeem Karimbux (Editor)

Clinical Cases in Prosthodontics

by Leila Jahangiri, Marjan Moghadam, Mijin Choi, Michael Ferguson

Clinical Cases in Restorative and Reconstructive Dentistry

by Gregory J. Tarantola



Clinical Cases in Endodontics

Takashi Komabayashi
University of New England

WILEY Blackwell

This edition first published 2018
© 2018 John Wiley & Sons, Inc.

All rights reserved. No part of this publication may be reproduced, stored in a retrieval system, or transmitted, in any form or by any means, electronic, mechanical, photocopying, recording or otherwise, except as permitted by law. Advice on how to obtain permission to reuse material from this title is available at <http://www.wiley.com/go/permissions>.

The right of Takashi Komabayashi to be identified as the author of the editorial material in this work has been asserted in accordance with law.

Registered Office

John Wiley & Sons, Inc., 111 River Street, Hoboken, NJ 07030, USA

Editorial Office

111 River Street, Hoboken, NJ 07030, USA

For details of our global editorial offices, customer services, and more information about Wiley products visit us at www.wiley.com.

Wiley also publishes its books in a variety of electronic formats and by print-on-demand. Some content that appears in standard print versions of this book may not be available in other formats.

Limit of Liability/Disclaimer of Warranty

The contents of this work are intended to further general scientific research, understanding, and discussion only and are not intended and should not be relied upon as recommending or promoting scientific method, diagnosis, or treatment by dental professionals for any particular patient. In view of ongoing research, equipment modifications, changes in governmental regulations, and the constant flow of information relating to the use of medicines, equipment, and devices, the reader is urged to review and evaluate the information provided in the package insert or instructions for each medicine, equipment, or device for, among other things, any changes in the instructions or indication of usage and for added warnings and precautions. While the publisher and authors have used their best efforts in preparing this work, they make no representations or warranties with respect to the accuracy or completeness of the contents of this work and specifically disclaim all warranties, including without limitation any implied warranties of merchantability or fitness for a particular purpose. No warranty may be created or extended by sales representatives, written sales materials or promotional statements for this work. The fact that an organization, website, or product is referred to in this work as a citation and/or potential source of further information does not mean that the publisher and authors endorse the information or services the organization, website, or product may provide or recommendations it may make. This work is sold with the understanding that the publisher is not engaged in rendering professional services. The advice and strategies contained herein may not be suitable for your situation. You should consult with a specialist where appropriate. Further, readers should be aware that websites listed in this work may have changed or disappeared between when this work was written and when it is read. Neither the publisher nor authors shall be liable for any loss of profit or any other commercial damages, including but not limited to special, incidental, consequential, or other damages.

Library of Congress Cataloging-in-Publication Data

Names: Komabayashi, Takashi, 1973- editor.

Title: Clinical cases in endodontics / edited by Takashi Komabayashi.

Description: Hoboken, NJ : Wiley, 2017. | Series: Clinical cases series | Includes bibliographical references and index. |

Identifiers: LCCN 2017020926 (print) | LCCN 2017021343 (ebook) | ISBN 9781119147114 (pdf) | ISBN 9781119147060 (epub) | ISBN 9781119147046 (pbk.)

Subjects: | MESH: Root Canal Therapy--methods | Endodontics--methods | Case Reports

Classification: LCC RK351 (ebook) | LCC RK351 (print) | NLM WU 230 | DDC 617.6/342--dc23

LC record available at <https://lcn.loc.gov/2017020926>

Cover Design: Wiley

Cover Images: (Column 1) Courtesy of Howard Foo;(Column 2) Courtesy of Qiang Zhu and Keivan Zoufan;(Column 3) Courtesy of Nathaniel Nicholson

Set in 10/13pt Univers LTStd by SPi Global, Chennai, India

CONTENTS

Contributors	ix
Acknowledgements	xi
Chapter 1 Introduction	1
<i>Takashi Komabayashi</i>	
Chapter 2 Diagnostic Case I	5
Tooth Fracture: Unrestorable <i>Suanhow Howard Foo</i>	
Chapter 3 Diagnostic Case II	11
Exploratory Surgery: Repairing Incomplete Fracture <i>Keivan Zoufan</i> <i>Takashi Komabayashi</i> <i>Qiang Zhu</i>	
Chapter 4 Emergency Case I	20
Interprofessional Collaboration between Medical and Dental <i>Andrew Xu</i>	
Chapter 5 Emergency Case II	27
Pulpal Debridement, Incision and Drainage (Intra-oral) <i>Victoria E. Tountas</i>	
Chapter 6 Emergency Case III	37
Pulpal Debridement, Incision and Drainage (Extra-oral) <i>Amr Radwan</i> <i>Katia Mattos</i>	

Chapter 7	Non-surgical Root Canal Treatment Case I	45
	Maxillary Anterior <i>Denise Foran</i>	
Chapter 8	Non-surgical Root Canal Treatment Case II	53
	Mandibular Anterior <i>Jessica Russo Revand</i> <i>John M. Russo</i>	
Chapter 9	Non-surgical Root Canal Treatment Case III	63
	Maxillary Anterior/Difficult case (Calcified Coronal ½ Canal System) <i>Andrew L. Shur</i>	
Chapter 10	Non-surgical Root Canal Treatment Case IV	72
	Maxillary Premolar <i>Daniel Chavarría-Bolaños</i> <i>David Masuoka-Ito</i> <i>Amaury J. Pozos-Guillén</i>	
Chapter 11	Non-surgical Root Canal Treatment Case V	79
	Mandibular Premolar <i>Takashi Okiji</i>	
Chapter 12	Non-surgical Root Canal Treatment Case VI	91
	Mandibular Premolar / Difficult Anatomy (three canals) <i>Savita Singh</i> <i>Gayatri Vohra</i>	
Chapter 13	Non-surgical Root Canal Treatment Case VII	98
	Maxillary Molar/Four Canals (MB1, MB2, DB, P) <i>Khaled Seifelnasr</i>	
Chapter 14	Non-surgical Root Canal Treatment Case VIII	105
	Mandibular Molar <i>Ahmed O Jamleh</i> <i>Nada Ibrahim</i>	

Chapter 15 Non-surgical Root Canal Treatment Case IX	113
Maxillary Molar /Difficult Anatomy (Dilacerated Molar Case Management) <i>Priya S. Chand</i> <i>Jeffrey Albert</i>	
Chapter 16 Non-Surgical Re-treatment Case I	122
Maxillary Anterior <i>Kana Chisaka-Miyara</i>	
Chapter 17 Non-surgical Re-treatment Case II	129
Maxillary Premolar <i>Yoshio Yahata</i>	
Chapter 18 Non-surgical Re-treatment Case III	136
Mandibular Molar <i>Bruce Y. Cha</i>	
Chapter 19 Periapical Surgery Case I	147
Maxillary Premolar <i>Pejman Parsa</i>	
Chapter 20 Periapical Surgery Case II	154
Apical Infection Spreading to Adjacent Teeth <i>Takashi Komabayashi</i> <i>Jin Jiang</i> <i>Qiang Zhu</i>	
Chapter 21 Periapical Surgery Case III	164
Maxillary Molar <i>Parisa Zakizadeh</i>	
Chapter 22 Perio-Endo Interrelationships	172
<i>Abdullah Alqaied</i> <i>Maobin Yang</i>	
Chapter 23 Traumatic Injuries	179
Avulsed and Root-Fractured Maxillary Central Incisor <i>Bill Kahler</i> <i>Louis M. Lin</i>	

Chapter 24 Incompletely Developed Apices **188**

Nathaniel T. Nicholson

Chapter 25 External/Internal Resorption **200**

*Keivan Zoufan
Takashi Komabayashi
Qiang Zhu*

Index **208**

CONTRIBUTORS

Editor

Takashi Komabayashi, DDS, MDS, PhD, Diplomate, American Board of Endodontics, Clinical Professor, University of New England College of Dental Medicine, Portland, Maine, USA.

Chapter Authors

Jeffrey Albert, DMD, Diplomate, American Board of Endodontics, Private Practice, Endodontic Associates, West Palm Beach, Florida, USA.

Abdullah Alqaied, DDS, MDS, Diplomate, American Board of Endodontics, Private Practice, Asnan Tower, Al-Salmiya, Kuwait.

Bruce Y. Cha, DMD, FAGD, FACD, FICD, Diplomate, American Board of Endodontics, Private Practice, Endodontic LLC, New Haven and Hamden; Section Chief, Endodontics, Department of Dentistry, Yale-New Haven Hospital, New Haven; Assistant Clinical Professor, Yale School of Medicine, New Haven; Assistant Clinical Professor, Division of Endodontology, School of Dental Medicine, University of Connecticut, Farmington, Connecticut, USA.

Priya S. Chand, BDS, MSD, Diplomate, American Board of Endodontics, Clinical Associate Professor, Division of Endodontics, University of Maryland Dental School, Baltimore, Maryland, USA.

Daniel Chavarría-Bolaños, DDS, MSc, PhD, Professor/Researcher, Facultad de Odontología, Universidad de Costa Rica, San José, Costa Rica.

Kana Chisaka-Miyara, DDS, PhD, Part-time Lecturer, Department of Pulp Biology and Endodontics, Tokyo Medical and Dental University, Tokyo, Japan.

Suanhow Howard Foo, DDS, Diplomate, American Board of Endodontics, Private Practice, Hacienda Heights, California, USA.

Denise Foran, DDS, Diplomate, American Board of Endodontics, Program Director/Advanced Specialty Program in Endodontics, Department of Veterans Affairs New York Harbor Healthcare System, New York, USA.

Nada Ibrahim, BDS, Saudi Board of Endodontics, University Staff Clinics, College of Dentistry, King Saud University, Riyadh, Saudi Arabia.

Ahmed O Jamleh, BDS, MSc., PhD, Assistant Professor of Endodontics, Restorative and Prosthetic Dental Sciences, College of Dentistry, King Saud bin Abdulaziz University for Health Sciences, National Guard Health Affairs, Riyadh, Saudi Arabia.

Jin Jiang, DDS, PhD, Diplomate, American Board of Endodontics, Private Practice, Endodontic LLC, New Haven and Hamden; Assistant Professor, Division of Endodontology, University of Connecticut School of Dental Medicine, Farmington, Connecticut, USA.

CONTRIBUTORS

Bill Kahler, DCLinDent, PhD, School of Dentistry, University of Queensland, Brisbane, Australia.

Takashi Komabayashi, DDS, MDS, PhD, Diplomate, American Board of Endodontics, Clinical Professor, University of New England College of Dental Medicine, Portland, Maine, USA.

Louis M. Lin, BDS, DMD, PhD, Diplomate, American Board of Endodontics, Professor, Department of Endodontics, New York University College of Dentistry, New York, USA.

David Masuoka-Ito, DDS, PhD, Researcher Professor, Department of Somatology, Universidad Autónoma de Aguascalientes, Aguascalientes, México.

Katia Mattos, DMD, Diplomate, American Board of Endodontics, Private Practice, Miami, Florida, USA.

Nathaniel T. Nicholson, DDS, MS, Diplomate, American Board of Endodontics, Private Practice, Galesville, MD; Clinical Assistant Professor, West Virginia University School of Dentistry, Morgantown, West Virginia, USA.

Takashi Okiji, DDS, PhD, Professor, Department of Pulp Biology and Endodontics, Graduate School of Medical and Dental Sciences, Tokyo Medical and Dental University, Tokyo, Japan.

Pejman Parsa, DDS, MS, Diplomate, American Board of Endodontics, Private Practice, West LA Endodontics, Los Angeles, California, USA.

Amaury J. Pozos-Guillén, DDS, MSc, PhD, Professor, Facultad de Estomatología, Universidad Autónoma de San Luis Potosí, San Luis Potosí, SLP, México.

Amr Radwan, BDS, Diplomate, American Board of Endodontics, Private Practice, Miami, Florida, USA.

Jessica Russo Revand, DMD, MS, Private Practice, Northern Virginia Endodontic Associates, Arlington, Virginia, USA.

John M. Russo, DMD, Associate Clinical Professor, Division of Endodontics, University of Connecticut School of Dental Medicine, Farmington, Connecticut, USA.

Khaled Seifelnasr, BDS, DDS, MS, Private Practice, Hudson, New Hampshire; Lecturer on Restorative Dentistry and Biomaterials Sciences, Harvard School of Dental Medicine, Boston, Massachusetts, USA.

Andrew L. Shur, DMD, Diplomate, American Board of Endodontics, Private Practice, Endodontic Associates, Portland, Assistant Clinical Professor, University of New England College of Dental Medicine, Portland, Maine, USA.

Savita Singh, DDS, Private Practice, New York, USA.

Victoria E. Tountas, DDS, Diplomate, American Board of Endodontics, Private Practice, Plano, Texas, USA.

Gayatri Vohra, DDS, Private Practice, Acton and Concord Endodontics, Lecturer on Restorative Dentistry and Biomaterials Sciences, Harvard School of Dental Medicine, Boston, Massachusetts, USA.

Andrew Xu, DDS, MS, Diplomate, American Board of Endodontics, Private Practice, Plano, Texas, USA.

Yoshio Yahata, DDS, PhD, Assistant Professor, Division of Endodontology, Department of Conservative Dentistry, Showa University School of Dentistry, Tokyo, Japan.

Maobin Yang, DMD, MDS, PhD, Diplomate, American Board of Endodontics, Assistant Professor, Department of Endodontology, Kornberg School of Dentistry, Temple University, Philadelphia, Pennsylvania, USA.

Parisa Zakizadeh, DDS, MS, Diplomate, American Board of Endodontics, Private Practice, La Jolla Dental Specialty Group, San Diego, California, USA.

Qiang Zhu, DDS, PhD, Diplomate, American Board of Endodontics, Professor, Division of Endodontology, University of Connecticut School of Dental Medicine, Farmington, Connecticut, USA.

Keivan Zoufan, DDS, MDS, Diplomate, American Board of Endodontics, Private Practice, Zoufan Endodontics, Los Altos and Cupertino, Assistant Professor of Dental Diagnostic Science, University of the Pacific, Arthur A. Dugoni School of Dentistry, San Francisco, California, USA.

ACKNOWLEDGEMENTS

The editor and contributors would like to acknowledge the great help they have received from colleagues and students.

Special support came from:

Elizabeth J. Dyer, MLIS, AHIP (Associate Dean of Library Services, Research & Teaching Librarian, University of New England); **Miki Furusho** PhD (Image analysis consultant, University of Connecticut); **Kathy Hooke**, MAT, JD (English language consultant); **Christine Lin** (Assistant); **Oran Suta** (Medical/Dental illustration, University of New England College of Osteopathic Medicine).

The following students at the University of New England College of Dental Medicine reviewed and provided invaluable feedback on this textbook:

Brittney Bell, Aparna Bhat, Dorothy Cataldo, Hannah Chung, Lindsey Cunningham, Sarah Georgeson, Andy Greenslade, Keith Hau, Anna Ivanova, Alex Katanov, Jonathan Nutt, Tara Prasad, Rishi Phakey, Christine Roenitz, Tarandeep Sidiura, Arina Sorokina, Shadbeh Taghizadeh, Eleanor Threet, Jackson Threet, Anh Tran, Robert Walsh, Minjin Yoo, Kenneth Yuth.

Professional clinical input and critical reviews were generously provided by the following valued colleagues (endodontists, endo residents and periodontists):

Anthony J. Carter, DDS, Advanced Specialty Program in Endodontics/Resident (Class of 2017), Department of Veterans Affairs New York Harbor Healthcare System, New York, USA.

Akira Hasuike, DDS, PhD, Assistant Professor, Nihon University School of Dentistry, Tokyo, Japan.

Rachel McKee Garoufalos, DMD, Private Practice, Manchester, New Hampshire; Assistant Clinical Professor, University of New England College of Dental Medicine, Portland, Maine, USA.

Rick Moser, DDS, Advanced Specialty Program in Endodontics/Resident (Class of 2016), Department of Veterans Affairs New York Harbor Healthcare System, New York, USA.

Lester Reid, DMD, MDS, Private Practice, Hartford, Assistant Clinical Professor, University of Connecticut Health Center, Farmington, Connecticut, USA.

Manuel Sato, DDS, Advanced Specialty Program in Endodontics/Resident (Class of 2020), University of Connecticut Health Center, Farmington, Connecticut, USA.

Chase Thompson, DMD, Advanced Specialty Program in Endodontics/Resident (Class of 2018), Department of Veterans Affairs New York Harbor Healthcare System, New York, USA.

Introduction

Takashi Komabayashi

LEARNING OBJECTIVES

- To understand the purpose, special features, and benefits of this book.
- To understand the scope and approach of each chapter.
- To understand the terminology and common frames of reference used.

Copiously illustrated in full color, *Clinical Cases in Endodontics* brings together actual endodontic clinical cases chosen by national and international master clinicians and leading academics, building from the simple to the complex and from the common to the rare. Part of the Wiley-Blackwell Clinical Cases series, and with cases ranging from nonsurgical root canal treatment to complicated therapy, this book presents practical, everyday applications accompanied by rigorously supported academic commentary in a unique approach that questions and educates readers about essential topics in clinical endodontics. The format of *Clinical Cases in Endodontics* fosters case-based, problem-based and evidence-based independent learning and prepares readers for case-based examinations. It is, therefore, useful as a textbook from which predoctoral dental students and postgraduate residents may learn about the challenging and absorbing nature of endodontic treatment. However, the book's range and depth of detail will also make it an excellent reference tool for practitioners whenever perplexing cases arise in the dental office.

Each chapter provides a brief recap of key theoretical concepts, situates cases within the framework of standard protocols, and considers the advantages and disadvantages of the clinical regimen. This approach enables student readers to build their skills, aiding their ability to think critically and independently. However, by simulating a step-by-step visual presentation, this book also facilitates development and refinement of technique regardless of one's years of experience in endodontic treatment. *Clinical Cases in Endodontics* will make all readers more confident in their understanding of endodontic treatment.

Composition of each Chapter (Chapters 2 to 25)

Clinical Cases in Endodontics adheres to the same four-part structure for each chapter.

1. Learning Objectives

Each chapter opens with a statement of learning objectives for that chapter, a format familiar from course syllabi at many dental schools or dental continuing education courses.

2. Clinical Case (With Radiographs and Pictures)

The focus of each chapter is a single case, presented in the case-based format of the American Board of Endodontics (ABE) Case History Exam. Since this book is intended for dental students and general dentists, as well as endodontic residents and endodontic specialists, the level of case difficulty may not be the same as that reflected in the ABE Case History Exam. All cases are real cases, however, chosen by master

clinicians and/or leading academics for uniqueness and complexity. Overall, the level of difficulty is high.

The following are common guidelines used by all authors for each chapter.

- The dental notation system in this textbook is the “Universal Tooth Designation System” used in the United States (i.e., tooth #1 to #32). If you are a student/resident/dentist outside the United States, it is likely that your country/region is using a different tooth designation system, such as the International Standards Organization designation system (ISO System) by Fédération Dentaire Internationale (FDI) World Dental Federation or Palmer method. International readers may consult Figure 1.1 to see how these systems relate to one another. International coverage and perspectives will be sought. The Pulpal & Apical Diagnostic Terminology (Figure 1.2) used in this textbook follows that published in the December 2009 special issue of the *Journal of Endodontics*. Also consulted were *Mosby’s Dental Dictionary* (Mosby 2013) and *Dentistry at a Glance* (Kay 2016).
- In each chapter, text, radiographs and pictures, including many follow-up radiographs and clinical photos, combine to provide sufficient and necessary detail for understanding each case. Taken together, the individual cases demonstrate the full scope of the field of endodontics.
- Unlike other endodontics textbooks, each chapter provides a detailed history, diagnosis, and treatment procedures for the case described. The case series focuses on using critical thinking and analysis to merge concepts and actual patient treatments.
- *Clinical Cases in Endodontics* uses a case- and evidence-based format throughout, with appropriate citations and references.

Structure of clinical cases

- Chief Complaint
- Medical History
- Dental History
- Clinical Evaluation (Diagnostic Procedures)
 - Examinations (Extra-oral and Intra-oral)
 - Diagnostic Tests (Summarized in Table)
 - Radiographic Findings
- Pretreatment Diagnosis
 - Pulpal
 - Apical
- Treatment Plan
 - Recommended
 - Alternative

- Restorative
- Prognosis (Favorable, Questionable, or Unfavorable)
- Clinical Procedures: Treatment Record
- Post-Treatment Evaluation

3. Five Self-Study Questions

The self-study questions will be useful at all levels to assess mastery of the concepts and techniques set forth in the chapter. A student might use them in studying for midterm and final exams at a dental school or residency program, an endodontic resident might use them to prepare for a mock oral examination, or an endodontist to prepare for board examinations. The self-study questions may also serve as an abstract and publications writing tool for endodontic professionals.

4. Answers to the Five Self-Study Questions (With References)

A full answer is provided for each self-study question, backed up by references to peer-reviewed publications (original articles and review articles).

Benefits of this book

Clinical Cases in Endodontics is not just another “how you do things” textbook. Nor is it simply a series of “good-looking root canals.” In addition to the stimulus of a step-by-step visual (photographic) presentation, similar to the ABE examinations, explanations of treatment modality and clinical background are supported by contemporary, evidence-based research. Cases include the whole scope of endodontics treatment, including medical and dental history, examination and diagnosis, treatments, and outcome assessments. The unique combination of breadth and depth gives rise to numerous benefits for a wide range of dental students, residents and endodontic practitioners. The book:

- supports analysis of problem etiology and application of critical thinking;
- fosters comparison and evaluation of alternative approaches, with rationales for plans of action and predicted outcomes;
- creates a simulation-type environment in which students/residents/dentists may engage in decision-making;
- allows for retrospective critiques of cases to identify error and its causes, as well as recognition of exemplary performance;
- encourages analysis and discussion of students’/ residents’/ dentists’ work products in comparison

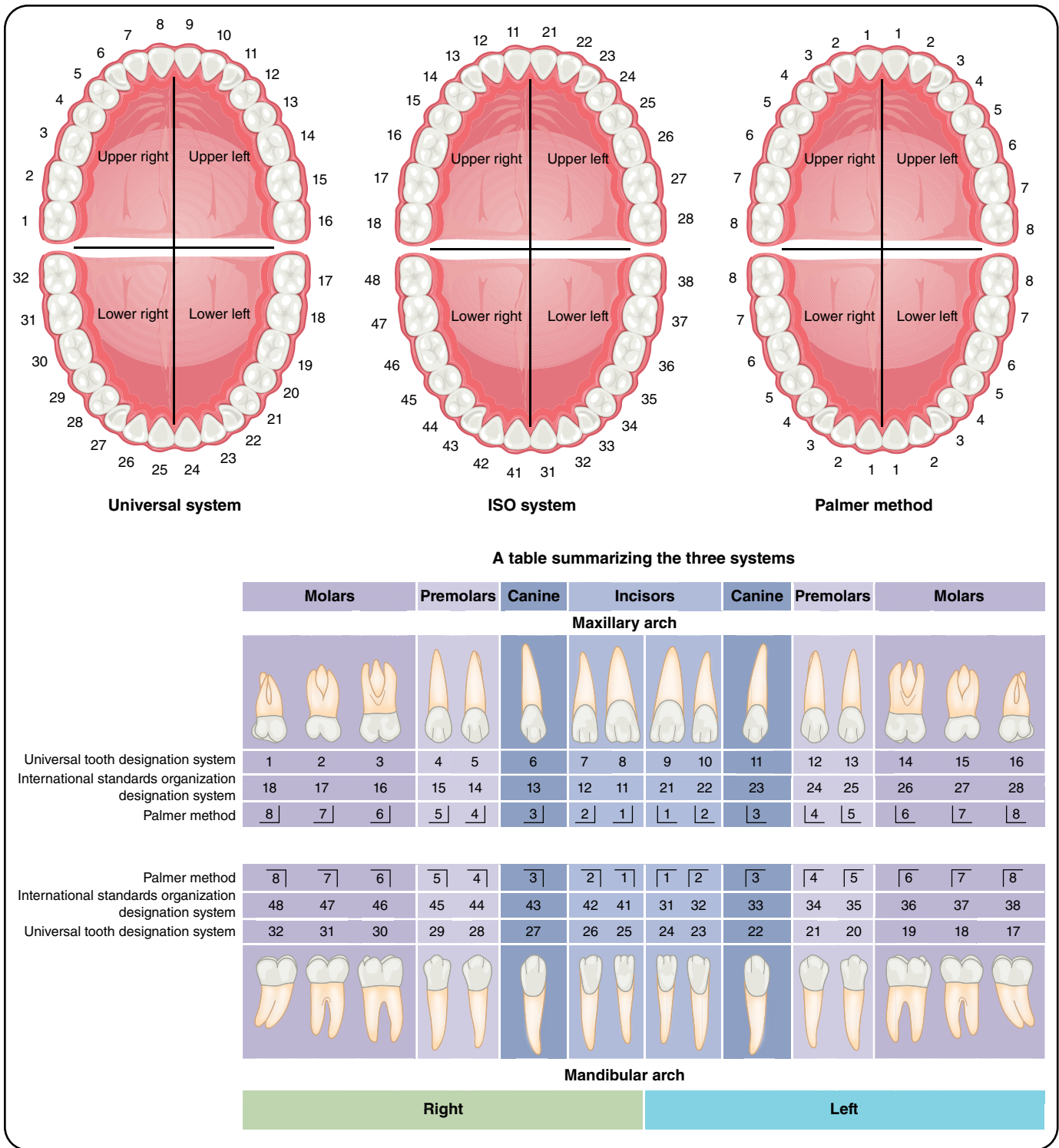


Figure 1.1 Tooth designation: three system summary.

- with best-evidence outcomes or other professional standards;
- encourages active learning methods, such as case analysis and discussion, critical appraisal of scientific

evidence in combination with clinical application and patient factors; and structured sessions in which students/ residents/ dentists reason aloud about patient care.

Pulpal:	
Normal pulp	A clinical diagnostic category in which the pulp is symptom-free and normally responsive to pulp testing.
Reversible pulpitis	A clinical diagnosis based upon subjective and objective findings indicating that the inflammation should resolve and the pulp return to normal.
Symptomatic irreversible pulpitis	A clinical diagnosis based on subjective and objective findings indicating that the vital inflamed pulp is incapable of healing. <i>Additional descriptors:</i> Lingering thermal pain, spontaneous pain, referred pain.
Asymptomatic irreversible pulpitis	A clinical diagnosis based on subjective and objective findings indicating that the vital inflamed pulp is incapable of healing. <i>Additional descriptors:</i> No clinical symptoms but inflammation produced by caries, caries excavation, trauma.
Pulp necrosis	A clinical diagnostic category indicating death of the dental pulp. The pulp is usually non-responsive to pulp testing.
Previously treated	A clinical diagnostic category indicating that the tooth has been endodontically treated and the canals are obturated with various filling materials other than intracanal medicaments.
Previously initiated therapy	A clinical diagnostic category indicating that the tooth has been previously treated by partial endodontic therapy (e.g., pulpotomy, pulpectomy).
Apical:	
Normal apical tissues	Teeth with normal periradicular tissues that are not sensitive to percussion or palpation testing. The lamina dura surrounding the root is intact, and the periodontal ligament space is uniform.
Symptomatic apical periodontitis	Inflammation, usually of the apical periodontium, producing clinical symptoms including a painful response to biting and/or percussion or palpation. It might or might not be associated with an apical radiolucent area.
Asymptomatic apical periodontitis	Inflammation and destruction of apical periodontium that is of pulpal origin, appears as an apical radiolucent area, and does not produce clinical symptoms.
Acute apical abscess	An inflammatory reaction to pulpal infection and necrosis characterized by rapid onset, spontaneous pain, tenderness of the tooth to pressure, pus formation, and swelling of associated tissues.
Chronic apical abscess	An inflammatory reaction to pulpal infection and necrosis characterized by gradual onset, little or no discomfort, and the intermittent discharge of pus through an associated sinus tract.
Condensing osteitis	Diffuse radiopaque lesion representing a localized bony reaction to a low-grade inflammatory stimulus, usually seen at apex of tooth.

Figure 1.2 Pulpal and apical diagnostic terminology.

References

AAE consensus conference recommended diagnostic terminology. (2009) *Journal of Endodontics* **35**, 1634.

Mosby (2013) *Mosby's Dental Dictionary*, 3rd edn. Amsterdam: Elsevier.

Kay, E. (2016) *Dentistry at a Glance*. Oxford: Wiley-Blackwell.

2

Diagnostic Case I: Tooth Fracture: Unrestorable

Suanhow Howard Foo

LEARNING OBJECTIVES

- To apply knowledge of dental anatomy to clinical procedures involving a cracked tooth.
- To be able to interpret radiographs used in endodontic diagnosis.
- To formulate a correct endodontic diagnosis and treatment plan based on a variety of clinical testing procedures, taking into account factors such as loss of tooth structure, bruxism, age, and gender.
- To understand the prognosis and incidence rates of the various types of root fractures.

	Molars			Premolars		Canine	Incisors				Canine	Premolars		Molars		
	Maxillary arch															
Universal tooth designation system	1	2	3	4	5	6	7	8	9	10	11	12	13	14	15	16
International standards organization designation system	18	17	16	15	14	13	12	11	21	22	23	24	25	26	27	28
Palmer method	8	7	6	5	4	3	2	1	1	2	3	4	5	6	7	8
	Mandibular arch															
Palmer method	8	7	6	5	4	3	2	1	1	2	3	4	5	6	7	8
International standards organization designation system	48	47	46	45	44	43	42	41	31	32	33	34	35	36	37	38
Universal tooth designation system	32	31	30	29	28	27	26	25	24	23	22	21	20	19	18	17
	Right								Left							

Chief Complaint

“I had excruciating pain last night, now I can’t touch my tooth.”

Medical History

The patient (Pt) was a 58-year-old male Caucasian. He presented with nothing significant in medical history and no allergies to any medications or to latex. Vital signs were: Blood pressure (BP) 132/87 mmHg, pulse 82 beats per minute (BPM), respiratory rate (RR) 17 breaths per minute.

The Pt was American Society of Anesthesiologists Physical Status Scale (ASA) Class II.

Dental History

Pt had on-and-off pain on the lower right quadrant for a few weeks and was referred for an evaluation of tooth #31. The tooth had a mesial (M) to distal (D) crack. The tooth was painful to touch and the Pt could not eat or bite on that tooth. Pt reported a history of bruxism.

Clinical Evaluation (Diagnostic Procedures)

Examinations

Extra-oral Examination (EOE)

No asymmetry, no lymphadenopathy, no deviation of jaw when opening, no swelling, and temporomandibular joint (TMJ) was within normal limits (WNL).

Intra-oral examination (IOE)

Oral cancer screening performed with all tissues WNL. Tooth #31 had a M to D crack. Periodontal exam showed probing depths from M to D of Facial (4 mm, 3 mm and 8 mm) and M to D of Lingual (4 mm, 4 mm and 8 mm). Tooth #31 had type 1 mobility. Tooth #30 had probing depths from M to D of Facial (4 mm, 3 mm and 4 mm) and M to D of Lingual (4 mm, 4 mm and 4 mm). Tooth #31 had pain with bite test and pain when occluding. Methylene blue dye and fiber optics showed fracture was through and through and extended below the cemento-enamel junction (CEJ).

Diagnostic Tests

Tooth	#29	#30	#31
Percussion	–	–	+
Palpation	–	–	–
Cold	Normal	Normal	–
Mobility	None	None	Class 1
Bite	–	–	+

+: Response to percussion, or bite stick test;
 – : No response to percussion, palpation, cold, or on bite stick test

Radiographic Findings

Tooth #31 had a radiolucency that extended from the D cervical area to the apex of the D root. A crack could be seen on the D portion of tooth #31 with the D restorative material fractured. (See Figures 2.1 and 2.2.)

Pretreatment Diagnosis

Pulpal

Pulp Necrosis, tooth #31

Apical

Symptomatic Apical Periodontitis, tooth #31

Treatment Plan

Recommended

Emergency: Extraction, tooth #31

Definitive: Extraction, tooth #31

Alternative

No treatment

Restorative

Implant or Fixed Prosthetics

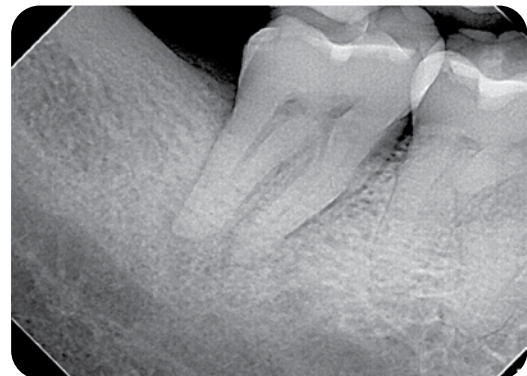


Figure 2.1 The initial radiograph of tooth #31. Notice the shallow restoration and the periapical rarefaction at the root apices.

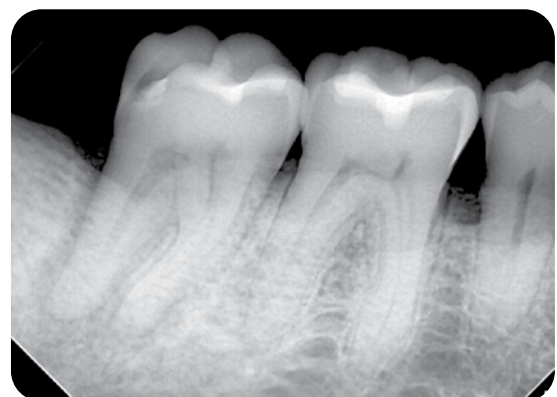

Figure 2.2 The extent of rarefaction in the distal root of tooth #31. Note how the radiolucency moves up to the alveolar crest.

Prognosis

Favorable	Questionable	Unfavorable
		X

Clinical Procedures: Treatment Record

First visit (Day 1): Exam: Pt was referred for an evaluation of tooth #31. Medical history (Hx) and vital signs were taken. Three periapical (PA) radiographs were prescribed in order to evaluate the PA area for possible infection and to determine the extent of the crack. The radiographs showed PA rarefactions (Figures 2.1 and 2.2) at root tips and bone loss in D root area. Clinical tests and exams were performed. Tooth #31 had an M to D crack that was verified with methylene blue (Figure 2.3) and a fiber optic light (Figures 2.4 and 2.5). The tooth could be separated in a buccal-lingual (B-L) manner with light touch. The defect could be seen extending to the pulpal floor. Pt was informed that the prognosis of the tooth was unfavorable and that extraction was needed to alleviate his pain and for healing to occur. The Pt accepted treatment (Tx) of extraction of Tooth #31. The extracted tooth was photographed and confirmed the initial diagnosis of a root fracture and split tooth (Figure 2.6).

Post-Treatment Evaluation

Second visit (1-week follow-up): Pt returned for a post-operative (PO) follow-up. The area around the extraction site of tooth #31 was neither inflamed nor swollen. Gingival tissue had already begun to fill in the

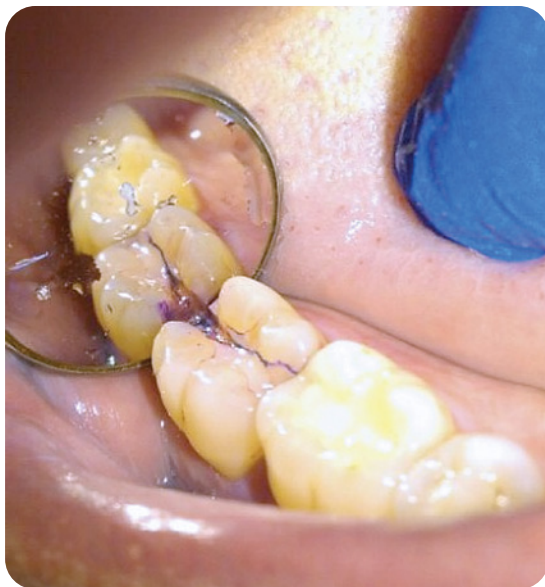

Figure 2.3 Mesial to distal crack of tooth #31, stained with methylene blue to better visualize the extent of the crack.

socket. The Pt was able to eat and brush his teeth in the lower right quadrant.

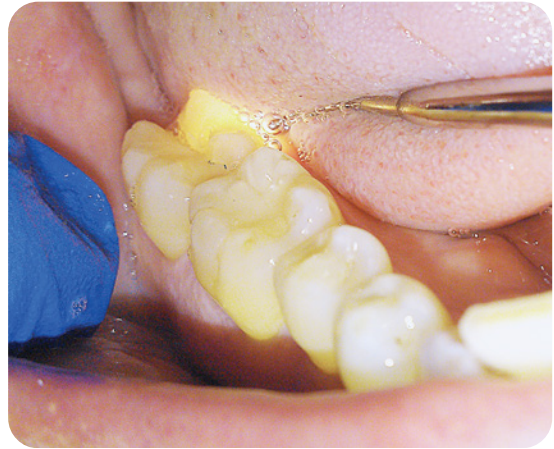


Figure 2.4 Fiber optic light illumination of tooth #31 shows that the crack goes below the CEJ. The light does not pass through from lingual to buccal.

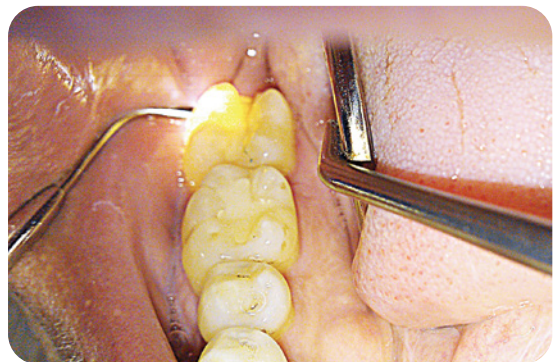

Figure 2.5 Fiber optic light was used on the buccal surface to confirm the crack.

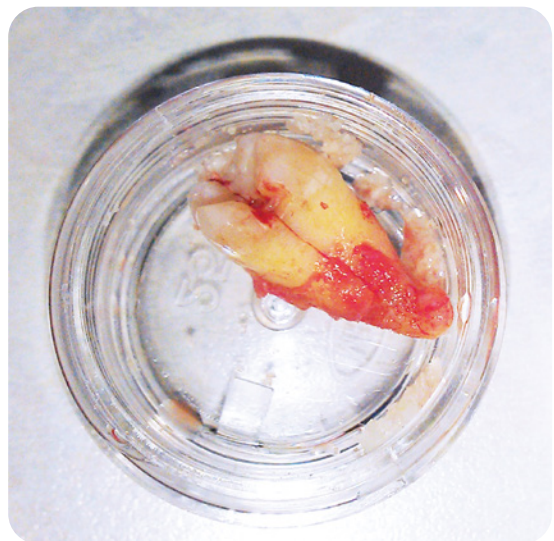

Figure 2.6 Diagnosis of a split tooth is confirmed after the extraction of tooth #31.

Self Study Questions

A. How is a fractured tooth diagnosed?

B. What are the types of cracks one may see in a suspected tooth fracture?

C. What is the prognosis for a cracked tooth?

D. How is a cracked tooth treated?

E. What is the incidence rate of fractures?

Answers to Self-Study Questions

A. There are multiple ways to determine whether or not a tooth is fractured. It is important to start with a good dental history of the tooth. A clinical exam should include a bite stick, ice for vitality testing, and a periodontal probing to check for deep narrow pockets. A radiographic exam is important to check for periapical rarefactions or possibly to reveal a fracture itself if it is large enough. Finally, a stain (methylene blue), or trans-illumination may be used to visualize the fracture. Sometimes the tooth may be mobile or a sinus tract may have developed due to fracture necrosis. If a tooth is non-vital with minimal or no restorations, suspect a crack or fracture (Berman & Kuttler 2010). The older the tooth, the more susceptible it is to fracture (Berman & Kuttler 2010). Cracked teeth are more commonly found in lower molars, followed by maxillary premolars (Cameron 1976). Another study found that lower 2nd molars were more likely to have cracks after root canal treatment (Kang, Kim & Kim 2016).

B. According to the American Association of Endodontics (Rivera & Walton 2008), there are five categories of crack:

- Craze lines: Only involving the enamel;
- Split tooth: Complete fracture through the tooth, usually centered mesial to distal;
- Fractured cusp: Usually non-centered and affecting one cusp;
- Cracked tooth: An incomplete fracture that extends from the crown to the subgingival area of the tooth; and
- Vertical Root Fracture (VRF): This may be symptomatic or non-symptomatic. The majority of the VRFs are associated with root-filled teeth. It may be a complete or an incomplete fracture.

C. The prognosis for a cracked tooth is always going to be questionable (Rivera & Walton 2008). The prognosis is always better if the crack does not extend to the pulp chamber floor (Turp & Gobetti 1996; Sim *et al.* 2016). Vital is better than necrotic (Turp & Gobetti 1996). The quality of the restoration and whether a full coverage crown may cover the

crack and other defects are considerations (Rivera & Walton 2008), as is whether an abscess or radiographic rarefaction is present prior to treatment. These two factors would lower the prognosis of the tooth in question (Berman & Kuttler 2010). One study found that cracked teeth had a two-year survival rate of 85.5% (Tan *et al.* 2006). Another study found that after five years, the survival rate of root-filled cracked teeth was 92%, with the odds of extraction increasing if the cracks were in the root (Sim *et al.* 2016). Finally, a recent study from Korea showed a 90%, two-year survival rate for a cracked tooth, probing depths greater than 6 mm being a significant factor in the prognosis (Kang *et al.* 2016).

D. After removal of all caries or previous restorations, the extent of the defect must be determined. If the crack or fracture transverses the pulpal floor or goes too deep subgingivally, then extraction of the tooth must be considered (Sim *et al.* 2016). If the tooth is vital with no narrow probing defects, abscesses, or periapical rarefactions, then restoring the tooth may be considered, along with endodontic therapy if needed, depending on the health of the pulp (Sim *et al.* 2016).

If a horizontal fracture occurs due to trauma, the position of the defect and the vitality of the pulp must be evaluated (Andreasen 1970). If the fracture is high enough, the coronal portion may be removed to see if a crown lengthening procedure along with endodontic therapy might salvage the tooth. If the defect is in the apical third, then an RCT to the coronal portion of the root is indicated (Andreasen 1970). If, however, the apical third has a rarefaction, an osteotomy may be performed to remove the infected piece.

Four types of outcome occur with intra-alveolar root fractures: (1) healing with calcified tissue; (2) interposition of connective tissue; (3) interposition of connective tissue and bone; and (4) interposition of granulation tissue without healing (Kim *et al.* 2016).

E. The incidence rate of VRFs is less than 3% (Zachrisson & Jacobsen 1975), and the rate of crown